

FERNANDA CAMPOS HERTEL

**CÉLULAS ESTROMAIS MESENQUIMAIS NA REPARAÇÃO DA PELE**

Dissertação apresentada à  
Universidade Federal de Viçosa,  
como parte das exigências do  
Programa de Pós-Graduação em  
Medicina Veterinária, para obtenção  
do título de *Magister Scientiae*.

VIÇOSA  
MINAS GERAIS – BRASIL  
2019

**Ficha catalográfica preparada pela Biblioteca Central da Universidade  
Federal de Viçosa - Câmpus Viçosa**

T

H531c                    Hertel, Fernanda Campos, 1991-  
2019                    Células estromais mesenquimais na reparação da pele /  
                          Fernanda Campos Hertel. – Viçosa, MG, 2019.  
                          vii, 41f. : il. (algumas color.) ; 29 cm.

Texto em inglês.

Orientador: Emily Correna Carlo Reis.

Dissertação (mestrado) - Universidade Federal de Viçosa.

Referências bibliográficas: f.35-41.

1. Medicina Regenerativa. 2. Terapia celular. 3. Engenharia de tecidos. I. Universidade Federal de Viçosa. Departamento de Veterinária. Programa de Pós-Graduação em Medicina Veterinária. II. Título.

CDD 22 ed. 636.08965

FERNANDA CAMPOS HERTEL

**CÉLULAS ESTROMAIS MESENQUIMAIS NA REPARAÇÃO DA PELE**

Dissertação apresentada à Universidade Federal de Viçosa, como parte das exigências do Programa de Pós-Graduação em Medicina Veterinária, para obtenção do título de *Magister Scientiae*.

APROVADA: 19 de fevereiro de 2019.




Fabrícia Hallack Loures




Gustavo Costa Bressan



Andréa Paheco Batista Borges  
(Coorientadora)



Fabrício Luciani Valente  
(Coorientador)



Emily Correna Carlo Reis  
(Orientadora)

## AGRADECIMENTOS

À minha família, pelo apoio que me é dado desde sempre e por sonharem junto comigo nesse caminho escolhido.

À minha orientadora, Professora Emily, por toda sua paciência e brilhantismo e por não me deixar desistir do projeto, sempre me incentivando a achar uma solução para os problemas encontrados. Foi engrandecedor trabalhar sob sua orientação.

Aos coorientadores, Professor Ricardo, Professor Fabrício e Professora Andrea, por sempre estarem disponíveis em me ajudar.

À amiga Aline, por sua amizade e pela imensa ajuda durante esse projeto, por aguentar meus dias de estresse, e pelos choros, gargalhadas e discussões que foram essenciais.

À amiga Dayana, pelas anestésias durante o experimento e especialmente pela amizade que ganhei durante o mestrado para a vida toda.

Às amigas Jéssica, Pollyanna, Tatiana e Juliana, pelo apoio, amizade e gargalhadas sem fim.

À Amanda, pela ajuda durante o cultivo celular e no experimento.

Aos estagiários e alunos de iniciação científica, pela ajuda no trabalho.

À professora Simone, por disponibilizar o laboratório de cultivo. Foi essencial para a finalização do projeto.

Aos funcionários do Departamento de Veterinária, por sempre estarem dispostos a me ajudar, pelo bom humor e sempre com um sorriso no rosto. Em especial, ao Claudiomiro, Fran, Rosi (esterilização), Grazi, Helen, Adão, Cláudio e Rosi (secretaria, salvadora dos pos-graduandos).

À CAPES, FAPEMIG e CNPq.

## SUMÁRIO

LISTA DE SIGLAS E ABREVIATURAS .....	iv
LISTA DE FIGURAS .....	v
RESUMO .....	vi
ABSTRACT .....	vii
GENERAL INTRODUCTION .....	1
CHAPTER I: Cutaneous wound healing and mesenchymal stromal cells therapy – a review .....	3
RESUMO.....	4
ABSTRACT .....	4
INTRODUCTION.....	5
CONCLUSIONS.....	16
CHAPTER II: Adipose tissue-derived mesenchymal stromal cells associated with platelet poor plasma for cutaneous wound healing .....	17
ABSTRACT .....	18
INTRODUCTION.....	19
METHODS .....	20
RESULTS.....	25
DISCUSSION .....	29
CONCLUSIONS.....	33
GENERAL CONCLUSIONS .....	34
REFERENCES .....	35

## LISTA DE SIGLAS E ABREVIATURAS

MSC: mesenchymal stromal cell

ASC: adipose tissue-derived mesenchymal stromal cell

BM-MSC: bone marrow-derived mesenchymal stromal cell

PPP: platelet-poor plasma

CO: control

ECM: extracellular matrix

PDGF: platelet-derived growth factor

EGF: epidermal growth factor

EGFR: epidermal growth factor receptor

FGF: fibroblast growth factor

TGF: transforming growth factor

VEGF: vascular-endothelial growth factor

IGF: insulin-like growth factor

HGF: hepatocyte growth factor

bFGF: basic fibroblast growth factor

IL: interleukin

TNF- $\alpha$ : tumor necrosis factor

ROS: reactive oxygen species

MMP: matrix metalloproteinase

DMEM: Dulbecco's modified Eagle Medium

PBS: phosphate-buffered saline

## LISTA DE FIGURAS

Figure 1: Isolation process of adipose-derived MSC. A, interscapular adipose tissue drying in filter paper. B, adipose tissue appearance after slicing. C, adipose tissue in collagenase suspension. D, adipose tissue appearance after digestion. ....	21
Figure 2: A, ASCs pellet in PBS, stained with membrane dye. B, preparing PPP suspension with stained cells before application. ....	23
Figure 3: Wound preparation. A, application of ACSs suspension in PPP. B, PPP gel in the wound. C, gauze with petrolatum covering the wound. D, transparent film dressing.....	23
Figure 4: Images by confocal microscopy 14 days after transplantation of rabbits' ASCs stained membrane dye, applied onto skin wound. Yellow Arrows: ASCs aggregates. White arrows: isolated ASCs.....	26
Figure 5: wound healing process at day 0,7 and 14. Notice the evident epithelization halo in day 7 of ASCs+PPP group (arrow heads). ....	27
Figure 6: A, Percentage of epithelialization at day 7 (A). Wound healing percentage in day 7 (B). Error bars represent standard deviation from the mean. Different symbols differ statistically ( $P < 0,05$ ). ....	27
Figure 7: Histopathologic sections of rabbit cutaneous wound in day 14, stained with HE. A, control group, moderate fibroplasia and inflammatory infiltrate, 100x, B, image of the same case in A, exhibiting another field with a giant cell within fibroblasts (white arrow), and less presence of eosinophils (black arrow head) 400x. C, PPP group, lower inflammatory infiltrate, 100x. D, same case in C, in evidence lower fibroblasts density and thicker collagen fibers, also lower number of eosinophils (yellow arrow head) 400x. E, ASC+PPP group, intense cellular infiltrate in the interface of dermis and epidermis, 100x. F, same case in E, evidencing the inflammatory cells with eosinophils (black arrows), 400x.....	28
Figure 8. Percentage of collagen type I and III at 14 days of healing of skin wounds. ....	29

## RESUMO

HERTEL, Fernanda Campos, M.Sc., Universidade Federal de Viçosa, fevereiro de 2019. **Células estromais mesenquimais na reparação de pele.** Orientador: Emily Correna Carlo Reis. Coorientadores: Andrea Pacheco Batista Borges, Fabrício Luciani Valente e Ricardo Seiti Yamatogi.

A cicatrização de feridas é um processo multi orquestrado com fases sobrepostas, denominado por hemostasia/inflamação, proliferação e remodelação e é influenciado por eventos biológicos e moleculares controlados, com fatores de crescimento, citocinas, células e matriz extracelular. A reparação de feridas tornou-se um problema global com grandes custos financeiros, associado a longo tratamento e afastamento do trabalho, necessitando muitas vezes de hospitalização, além do custo pessoal para o paciente e familiares envolvidos. As pesquisas a novos métodos, como engenharia de tecidos e medicina regenerativa, visam reduzir o tempo de recuperação, os custos relacionados e melhorar a regeneração tecidual. Neste contexto, a terapia celular, especialmente as células estromais mesenquimais (MSCs), demonstrou um grande potencial para a cicatrização de feridas. A forte capacidade de proliferar e diferenciar e os efeitos imunomoduladores são suas principais características para a medicina regenerativa, relacionado ao seu efeito parácrino pela secreção de fatores de crescimento e citocinas. O objetivo com este trabalho foi avaliar a influência das células mesenquimais estromais derivadas do tecido adiposo (ASCs) no reparo de feridas, usando plasma pobre em plaquetas (PPP) para promover a adesão celular na ferida, bem como discutir sobre os principais componentes do processo de reparo e como as MSCs podem influenciar suas ações. Neste estudo, ASCs associadas com PPP para o tratamento de feridas cutâneas de coelhos, e suas ações foram avaliadas por análise macroscópica e histopatológica. Nossos resultados sugerem que ASC+PPP foram capazes de acelerar a epitelização e a cicatrização de feridas na fase inicial de proliferação e aumentaram o infiltrado celular em estágio tardio de proliferação. Além disso, PPP sozinho mostrou um tecido de granulação mais avançado em comparação ao grupo controle e ASC + PPP, sugerindo um novo método para a terapia de feridas.

## ABSTRACT

HERTEL, Fernanda Campos, M.Sc., Universidade Federal de Viçosa, February, 2019. **Mesenchymal stromal cells in skin wound healing.** Adviser: Emily Correna Carlo Reis. Co-advisers: Andrea Pacheco Batista Borges, Fabrício Luciani Valente and Ricardo Seiti Yamatogi.

Wound healing is a multi-orchestrated process with overlapping phases, called hemostasis / inflammation, proliferation and remodeling, and is influenced by controlled biological and molecular events, with growth factors, cytokines, cells and extracellular matrix. The difficulty of wound repair is common and has become a global problem with large financial costs, associated with long treatment and withdrawal from work, often requiring hospitalization, as well as the personal cost to the patient and family members involved. Research to new methods such as tissue engineering and regenerative medicine, aimed at reducing recovery time, related costs and improving tissue regeneration. In this context, cell therapy, especially mesenchymal stromal cells (MSCs), has shown great potential for wound healing. The strong ability to proliferate and differentiate, and its immunomodulatory effects are the main characteristics for regenerative medicine, related to its paracrine effect by the secretion of growth factors and cytokines. The objective with this work was to evaluate the influence of adipose tissue-derived mesenchymal stromal cells (ASC) on wound repair, using platelet-poor plasma (PPP) to promote cell adhesion in the wound, as well as discussing the main components of the repair process and how MSCs can influence their actions. In this study, ASCs were associated with PPP for cutaneous wounds of rabbits, and their actions were assessed by macroscopic and histopathological analysis. Our results suggest this association were able to accelerate epithelialization and wound healing in the early stage of proliferation and increased cellular infiltrate in the late stage of proliferation. In addition, PPP alone showed a more mature granulation tissue compared to the control and ASC + PPP groups, suggesting a new method for wound therapy.

## GENERAL INTRODUCTION

Wound repair is a global issue with large financial costs often requiring hospitalization, associated with long treatments and withdrawal from work, , all this associated to the personal cost for the patient and family members (DA ROSA SILVA et al., 2017; FONDER et al., 2008). Numerous factors can cause delay in wound healing, which can be systemic or local ones, such as venous or arterial insufficiency, diabetes, renal disease, trauma, advanced age, ischemia, maceration of tissue, infection, disruption of the regulation of the inflammatory process, compromised nutritional or immune status (OJEH et al., 2015). These many causes still don't have a standard treatment, what lead the researches to novel methods, such as tissue engineering and regenerative medicine, aiming at reaching the entire regeneration of the skin, both histologically and functionally, together with the reduction in recovering time and costs related.

In this context, MSCs emerge as a promising option for wound repair because of their ability of interacting with wound environment and modulate their activity to release multiple factors, which improves the wound healing process (KANJI; DAS, 2017).

Adipose tissue represents a source of abundant stem cells, presenting a frequency of MSCs around 1 in 100 cells, about 500 times more than in the bone marrow (FRASER et al., 2006). Numerous studies have demonstrated the potential of adipose tissue-derived mesenchymal stromal cells (ASCs) improving wound healing by accelerating epithelization and decreasing wound size (EBRAHIMIAN et al., 2009; KIM et al., 2007; KIM; PARK; SUNG, 2009; NIE et al., 2011).

For a successful result, a suitable carrier is necessary to delivery these cells into the wound. Many carrier matrixes have been tested of different origins, autologous, homologous, heterologous and synthetic as well. An autologous matrix, platelet-poor plasma (PPP) have an extensive fibrin network, and showed to have potential for temporary matrix to provide a scaffold for local cell migration and adhesion, and thus, a candidate for

mesenchymal stromal cell carrier (HATAKEYAMA et al., 2014; YANG et al., 2017).

Therefore, the aim in this work was to evaluate the influence of ASCs in wound repair using PPP to improve cell adhesion to the wound site as well as to discuss about the major components in the healing process and how MSCs may influence their actions.

## CHAPTER I

### **Cutaneous wound healing and mesenchymal stromal cells therapy – a review**

Fernanda Campos Hertel et al.

## **Cutaneous wound healing and mesenchymal stromal cells therapy – a review**

### **Cicatrização de feridas cutâneas e a terapia com células estromais mesenquimais – uma revisão**

#### **RESUMO**

A cicatrização de feridas é um processo fisiológico essencial e consiste em fases sobrepostas orquestradas por muitos componentes, como células, fatores de crescimento e citocinas. A ferida da pele pode ser fechada por regeneração ou reparo. A primeira descreve a substituição específica do tecido, como a epiderme superficial, e, no último, a pele cicatriza por fibrose e formação de cicatriz. Qualquer interferência no processo, como diabetes e infecção, pode resultar em cura ineficiente. Portanto, as feridas crônicas geralmente demandam atenção médica de longo prazo e consomem uma quantidade substancial de despesas. As células estromais mesenquimais (MSCs) demonstraram um grande potencial para a regeneração de feridas. Estudos mostraram que essas células podem atenuar a resposta inflamatória secretando fatores de crescimento e citocinas, juntamente com o recrutamento de células locais para o processo de cicatrização. Nesta revisão, destacamos os principais componentes que desempenham um papel na cicatrização de feridas cutâneas, como fatores de crescimento, citocinas, células e terapia com MSCs.

**Palavras-chave:** células inflamatórias; citocinas; fatores de crescimento; terapia celular; medicina regenerativa; pele.

#### **ABSTRACT**

Wound healing is an essential physiological process and consists in overlapping phases orchestrated by many components, such as cells, growth factors and cytokines. The skin wound can be closed by regeneration or repair.

The first describes the specific substitution of the tissue, like the superficial epidermis, and in the last, the skin heals by fibrosis and scar formation. Any interference in the process such as diabetes and infection can result in inefficient healing. Therefore, chronic wounds often demand a major, long-term medical-attention and consumes a substantial amount of expenses. Mesenchymal stromal cells (MSCs) have demonstrated a great potential for wound healing. Studies showed that these cells can attenuate the inflammatory response by secreting growth factors and cytokines, together with recruiting local cells for the healing process. In this review, we highlight the main components that play a role in cutaneous wound healing, such as growth factors, cytokines, cells and MSCs therapy.

**Key-words:** cell therapy; cytokines; growth factors; inflammatory cells; regenerative medicine; skin;

## INTRODUCTION

Wound healing is an essential physiological process to maintain skin integrity after trauma. It consists in sequential and overlapping phases that include hemostasis/inflammation, proliferation and remodeling (LINDLEY et al., 2016), and involves the extracellular matrix (ECM), cells, growth factors, cytokines and chemokines (BEHM et al., 2012; HYNES, 2009; REINKE; SORG, 2012). The healing process depends on local factors, systemic mediators (BEHM et al., 2012), the underlying disease, and the type of injury (SCHREML et al., 2010).

Any interference in the process can result in inefficient heal, such as diabetes and infection. Therefore, chronic wounds often demands a major, long-term medical-attention and consumes a substantial amount of expenses (KANJI; DAS, 2017). The need for new therapies emerges searching for a more efficient method capable of optimizing the wound healing process.

In this context, cell therapy, specially MSCs have demonstrated a great potential for wound healing. The strong capacity to proliferate and differentiate together with immunomodulatory effects are their major characteristics for regenerative medicine. Studies showed that these cells can attenuate the

inflammatory response by influencing the transition from inflammatory to the proliferative phase (ENNIS; SUI; BARTHOLOMEW, 2013; NUSCHKE, 2014), mostly related to their paracrine effect by secreting growth factors and cytokines (NIE et al., 2011).

In this review, we aimed to highlight the main components that play a role in cutaneous wound healing and how MSCs can improve their actions.

## **Wound healing**

The skin wound can be closed by regeneration or by cicatrization. The first describes the specific substitution of the tissue, like the superficial epidermis and underlying dermis, and in the last, the skin heals by fibrosis and scar formation that is characterized as the main form in adult skin wound healing (REINKE; SORG, 2012).

The healing process is initiated after injury by the release of various growth factors, cytokines, and low molecular weight compounds from the serum of injured blood vessels and platelet degranulation. Injury of the blood vessels also leads to the formation of the blood clot, which is composed of reticulated fibrin, and extracellular proteins, and serves as a matrix for invading cells to migrate to the wound bed and a source of growth factors (REINKE; SORG, 2012; WERNER; GROSE, 2003)

After skin injury, the sub-endothelium collagen activate platelet aggregation, resulting in degranulation and releasing chemokines and growth factors (WANG et al., 2018). In the inflammatory phase chemokines induce the recruitment of different cells to the wound site and mediators initiate cell migration and proliferation by activating specific receptors and intracellular mechanisms (BEHM et al., 2012). Neutrophils are recruited by de-granulated platelets into the wound site and stay for 2-5 days working as chemoattractant to other cells and cleanse debris and bacteria, followed by macrophages that facilitate phagocytosis of bacteria and damaged tissue (REINKE; SORG, 2012; WANG et al., 2018).

In the proliferative phase, the wound surface is covered with granulation tissue and start restoring the vascular network. These occur by migration of local fibroblasts on and within the fibrin network. Therefore, fibroblasts

synthesize collagen, fibronectin and other substances needed for the new matrix of connective tissue. Subsequently, the proliferation of fibroblasts decline whiles the synthesis of collagen increases, adjusting the balance between synthesis and degradation of ECM (REINKE; SORG, 2012). The differentiation, proliferation and migration of epidermal keratinocytes are responsible for reepithelization of the wound edges after the wound bed has been established (SCHREML et al., 2010).

Remodeling is the last phase of wound healing, and can last up to years after injury. The apoptosis of cells stops the granulation tissue formation, and a mature wound is formed. The collagen type III produced in the proliferative phase is now replaced by collagen type I, which is organized in parallel bundles, different from the normal healthy dermis (basket-weave collagen). Finally, angiogenic process and wound blood flow declines and the metabolic activity stops (REINKE; SORG, 2012).

#### Role of growth factors

The wound healing is a complex multicellular process. It depends on several growth factors and cytokines that regulate a complex signaling network altering the growth by both stimulating and inhibiting processes such as cellular proliferation, differentiation, migration, and adhesion (BARRIENTOS et al., 2016; BENNETT; SEHULTZ, 1993). Once a growth factor is released it can act by autocrine, paracrine and endocrine stimulation (TRAVERSA; SUSSMAN, 2001).

Several growth factors have influence in wound healing, among the most important ones are: platelet-derived growth factor (PDGF), epithelial growth factor (EGF), fibroblast growth factor (FGF), transforming growth factor (TGF), vascular endothelial growth factor (VEGF), , and insulin growth factor (IGF) (MASI et al., 2016).

- Platelet-derived growth factor

PDGF has functions in all stages of wound healing (BARRIENTOS et al., 2016) and is a key mediator in the process. Its importance is highlighted

by being the first recombinant growth factor approved for topical application to accelerate wound closure (CORNICK et al., 2014).

The inflammatory response is initiated with the chemotaxis promoted by PDGF, released from degranulating platelets upon injury, stimulating mitogenicity and chemotaxis of neutrophils, macrophages, fibroblasts, and smooth muscle cells (HELDIN; WESTERMARK, 1999; WERNER; GROSE, 2003). In addition, it enhances proliferation of fibroblasts and production of extracellular matrix by these cells (WERNER; GROSE, 2003).

The secreted PDGF in the proliferation phase, along with extracellular matrix molecules stimulate the differentiation of fibroblasts to produce collagen. Fibroblasts are the major responsible for the synthesis, deposition, and remodeling of the extracellular matrix providing strength to the wound (CORNICK et al., 2014).

During the epithelialization phase of wound healing, PDGF up-regulates the production of insulin growth factor 1 (IGF-1) and thrombospondin-1, that are responsible for increase keratinocyte motility and protects proteolytic degradation of PDGF, respectively (BARRIENTOS et al., 2016).

It is important to highlight that PDGF is decreased in chronic wounds due to its susceptibility to the proteolytic environment found in the chronic wound (BARRIENTOS et al., 2016). Topical application of platelet-derived growth factor-BB (PDGF-BB) may accelerate tissue repair of impaired chronic wounds. However, the vast literature presents conflicting reports of its efficacy in animal models (UHL, et al., 2003; GOWDA et al., 2013; PARK et al., 2014). As an example, albeit a preview study showed that topical PDGF accelerated the rate of wound healing and reduced the TNF- $\alpha$  concentrations in both normal and ischemic wounds in rats (GOWDA et al., 2013), another one showed that topical PDGF did not improved wound healing in diabetic mice (PARK et al., 2014).

- Epithelial growth factor

Epidermal growth factor (EGF) is present in the corporal fluid and platelets, and plays a role in wound healing by stimulating proliferation and migration of keratinocyte, endothelial cells, and fibroblast and thus, facilitates

dermal regeneration (BODNAR, 2013; DINH; BRAUNAGEL; ROSENBLUM, 2015).

EGF receptor (EGFR) is decreased in keratinocytes surface in the margins of non-healing wounds, suggesting a crucial factor in chronic wounds and highlighting their importance in wound repair, since keratinocyte at the nonhealing edge have diminished ability to respond to EGF, as the EGFR is not in place to transmit the signal (BREM et al., 2007). A study using a wound dressing composed of hydroxyapatite and collagen containing EGF and vitamin C to treat skin wounds in diabetic mice, showed that it has the potential to facilitate production of VEGF (vascular endothelial growth factor) and HGF (hepatocyte growth factor) *in vitro* and to enhance granulation tissue formation associated with angiogenesis and collagen deposition *in vivo* as compared with other wound dressings (NIIYAMA; KUROYANAGI, 2014).

- Fibroblast growth factor

FGF family plays an important role in the re-epithelization phase. They are produced by keratinocytes, fibroblasts, endothelial cells, smooth muscle cells, chondrocytes, and mast cells. The presence of FGF-2 or bFGF (basic FGF) is important as a stimuli for fibroblast migration and proliferation, thus granulation tissue formation and re-epithelization (BARRIENTOS et al., 2016; BEHM et al., 2012).

For improving wound healing, bFGF has shown good results combined with topical oxygen therapy in burn wounds (NIE et al., 2010). A more recent clinical research reported that, bFGF treatment prevents scar contractures and hypertrophic scars (HAYASHIDA et al., 2016).

- Transforming growth factor

Transforming growth factor (TGF) is produced by platelets, macrophages, lymphocytes and hepatocytes. TGF- $\alpha$  act as mitogenic and chemotactic for keratinocytes and fibroblasts (SPACCAPELO, 2016) and TGF- $\beta$  is important for matrix remodeling and angiogenesis by inducing the expression of MMP-9 (matrix metalloproteinase 9) (LAMAR; IYER; DIPERSIO, 2008). In addition, TGF- $\beta$  induces the down-regulation of MMP-1, thereby

sustaining the balance between matrix synthesis and degradation (YUAN; VARGA, 2001). TGF- $\beta$ 3 has been found in high levels in fetal scarless wound healing and has promoted scarless healing in adults (SPACCAPELO, 2016). Eosinophils are also a source of TGF- $\alpha$  and  $\beta$ 1 in cutaneous wound (TODD et al., 1991).

- Vascular endothelial growth factor

Although several different mediators regulate angiogenesis, VEGF is believed to be one of the most important angiogenic mediators during wound healing (JOHNSON; WILGUS, 2014), also for lymphangiogenesis and vascular permeability (CORNICK et al., 2014). VEGF-A is produced by endothelial cells, keratinocytes, fibroblast smooth muscle cells, platelets, neutrophils and macrophages (BARRIENTOS et al., 2016).

During the course of normal wound repair, high levels of VEGF are produced, resulting in a vigorous angiogenic response. However, the levels of active VEGF protein tend to be abnormally decreased in individuals with chronic wounds, like observed in diabetic patients (JOHNSON; WILGUS, 2014).

A study demonstrated the relationship between the E2F1 transcription gene and cutaneous wound repair. The results showed that in E2F1 deletion resulted in higher expression of VEGF in mice, thus increasing neovascularization and recruitment of macrophages, in addition to the greater amount of collagen and thickness of the dermis (WANG et al., 2016).

Another study showed the effect of VEGF in diabetic wound in mice. The protein expression levels of VEGF increased in the normal control group and decreased in the diabetic model group and the relative expression quantity of VEGF mRNA in the normal control group was obviously higher than in the diabetic model group. Therefore, VEGF play important roles in diabetic wound healing and the decrease of their expression level may lead to lack of angiogenesis (LIN et al., 2017).

- Insulin-like growth factor

Insulin-like growth factor I (IGF-1) participates during normal wound healing process. However, diabetic patients show decreased levels of IGF-1 (BRUHN-OLSZEWSKA et al., 2012).

IGF-1 is mitogen for keratinocytes, and stimulates the production of collagen and the synthesis of proteoglycans by skin fibroblasts. The main source of circulating IGF1 in the postnatal life is the liver, but it may also be produced in other tissues where it possesses a paracrine activity (LEONOV et al., 2015).

The effects of topic 1% and 3% IGF-1 were analyzed on skin wound healing in diabetic and non-diabetic rats. The results showed a more rapid re-epithelialization of wounds treated with IGF in the macroscopic observations and the treatment increased the expression of myofibroblasts (ACHAR et al., 2014).

#### Role of cytokines

Several cytokines are present at the wound site, and their role are interconnected with all events in the healing process. Thus, a balance between inflammatory and anti-inflammatory cytokines is essential for the successful repair (HU et al., 2010).

##### - Pro-inflammatory Cytokines

The pro-inflammatory cytokines, IL-1 $\alpha$ , IL-1 $\beta$ , IL-6 and TNF- $\alpha$  play an important role in wound repair and the coordinated expression of these cytokines is likely to be important for normal repair. The major source of these cytokines is polymorphonuclear leukocytes and macrophages, but seems to be expressed in some resident cell type. They participate in several process at the wound site, including stimulation of keratinocyte and fibroblast proliferation, synthesis and breakdown of extracellular matrix proteins, fibroblast chemotaxis, and regulation of the immune response (WERNER; GROSE, 2003).

The balance among these cytokines and their receptors seems to be as important as their actions in wound healing. The IL-1 receptor antagonist (IL-1ra) is up-regulated during the inflammatory phase, and as shown by Ishida et

al., IL-1 $\alpha$  deficient mice resulted in delayed wound healing by the decreased gene expression of VEGF, suppressing TGF- $\beta$ -mediated signaling pathway, which is crucial for collagen deposition and vascular endothelial growth factor-mediated neovascularization in wound healing (ISHIDA et al., 2006).

Among the various pro-inflammatory effects attributed to IL-6, those closely related to the repair process are, at an earlier stage, its chemoattractant effects on neutrophils, and at the later stage, the mitotic induction of keratinocytes (BALBINO; PEREIRA; CURI, 2005). The importance of IL-6 has been showed in several studies (LIN et al., 2003; MCFARLAND-MANCINI et al., 2010). Lin et al., demonstrated that in IL-6 knock-out mice the reduction of wound area was delayed with attenuated leukocyte infiltration, re-epithelialization, angiogenesis, and collagen accumulation (LIN et al., 2003).

#### - Anti-inflammatory cytokines

One of the most important anti-inflammatory cytokines known to play a role in wound healing is IL-10. As the main sources of IL-10 mRNA, epidermal cells and mononuclear infiltrate were identified. IL-10 acts in limitation and termination of inflammatory responses and regulates growth and differentiation of keratinocytes and endothelial cells (WERNER; GROSE, 2003).

Sato et al. (1999) demonstrated that IL-10 inhibited the infiltration of neutrophils and macrophages toward the site of injury. IL-10 also inhibited overexpression of C-C chemokines (monocyte chemoattractant protein-1, macrophage inflammatory protein-1 $\alpha$ ) and proinflammatory cytokines (IL-1 $\beta$ , IL-6, tumor necrosis factor- $\alpha$ ) *in vivo*. In addition, more recently evidences showed that IL-10 has the inhibitory effects on the excessive deposition of extracellular matrix components, and also that it can potentially participate for the prevention and reduction of skin scarring (SHI et al., 2013).

#### Role of cells

Neutrophils are the predominant cells in the inflammation phase, beginning to appear during the first 48 hours and diminishing after 24-36h due to apoptosis (QING, 2017). Cytokines (mainly IL-1 and TNF- $\alpha$ ) produced by

macrophages, mast cells, stromal cells and other mediators, act on endothelial cell receptors, inducing these cells to express adhesion molecules for neutrophils, also inducing the production of nitric oxide, mainly by macrophages. The expression of adhesion proteins is one of the most important element for the migration of neutrophils (BALBINO; PEREIRA; CURI, 2005).

Neutrophils also have antimicrobial activity by secreting a variety of substances (reactive oxygen species (ROS), antimicrobial peptides, and antimicrobial proteases) and by phagocytosis. In addition, neutrophils secrete cytokines and growth factors that act as chemotactic for inflammatory cells, and promote the proliferation of fibroblasts, keratinocytes, and endothelial cells (LAROUCHE et al., 2018). During apoptosis, neutrophils release cytokines that has chemotactic effect in monocytes, which once in the wound site differentiate into macrophages. They start to arrive in the wound site 5 to 6 hours and can remain for weeks (LAROUCHE et al., 2018).

Macrophages play a central role in inflammatory phase and all the stages of repair. They produce and orchestrate cytokines and growth factors which stimulates the proliferation of inflammatory cells and endothelial cell replication (IL-1) and act as mitogen for fibroblasts (TNF- $\alpha$  and bFGF), and several other functions as well. In addition, macrophages phagocytoses apoptotic cells debris and bacteria (QING, 2017).

Depending on the stimulus, activation of macrophages is classified in M1 and M2 states. The first one results in a highly pro-inflammatory phenotype, which becomes a source of pro-inflammatory cytokines. The second one is mediated by IL-4 and/or IL-13 (QING, 2017). During the formation of new tissue, micro environmental cues trigger macrophages to transition into a functionally and phenotypically anti-inflammatory state, the so-called M2, and they begin secreting anti-inflammatory cytokines, such as TGF- $\beta$ 1 (LAROUCHE et al., 2018), PDGF, bFGF (QING, 2017) which promotes ECM synthesis by fibroblasts and wound contraction (LAROUCHE et al., 2018).

Responding to macrophage-synthesized growth factors, fibroblasts begin to infiltrate and degrade the fibrin clot by producing various matrix metalloproteinases (MMPs), replacing it with ECM components, such as collagen, glycoproteins, proteoglycans, laminin, thrombospondin,

glycosaminoglycans, hyaluronic acid and heparan sulphate (BAINBRIDGE, 2013). In the granulation tissue, fibroblasts change their phenotype by acquiring  $\alpha$ -SM actin expression in microfilament bundles or stress fibers. As a result, they become myofibroblasts and exhibit contractile properties, which can improve the contraction and maturation of the granulation tissue, reducing wound size (DARBY et al., 2014).

An important cell type for barrier maintenance is keratinocyte, the major cellular component of the epidermis, and also important for its restoration upon injury through a process known as epithelialization (PASTAR et al., 2014). This restoration starts when keratinocytes lose their adhesions to adjacent cells and to the basal lamina. Therefore, this release allows the cells to migrate from the wound edges to the newly formed granulation tissue, while other cells start to proliferate (PASTAR et al., 2014; QING, 2017).

#### - Role of Mesenchymal stromal cells

Numerous studies report the benefits of MSCs therapy in wound healing through mechanisms still being elucidated (ZEBARDAST; LICKORISH; DAVIES, 2010; NIE et al., 2011; KIM et al., 2013b; MARTINELLO et al., 2018), but their influence in biological and molecular events in the wound is clear.

As said above, growth factors participate in all phases of wound healing, and MSCs can influence their expression in the wound bed. Nie et al. (2011) showed a paracrine action played by MSCs, found to secrete angiogenic cytokines in vitro and in vivo, including VEGF, HGF, and FGF2, which increase neovascularization and enhance wound healing in injured tissues. Shohara et al. (2012), showed a similar result using human umbilical cord perivascular cells. These cells promoted wound healing via multifaceted paracrine mechanisms, increasing IL-10, TGF- $\beta$ 1, VEGF-1 and angiopoietin-1.

The influence of MSCs in the wound healing process can be interconnected, as the process itself is. Chen et al. (2008) showed that bone marrow derived mesenchymal stem cells (BM-MSC) can secrete greater amounts of VEGF-a, IGF-1, EGF, keratinocyte growth factor, angiopoietin-1, stromal derived factor-1, macrophage inflammatory protein-1 $\alpha$  and  $\beta$  and erythropoietin, compared to dermal fibroblasts. Also, wound sections treated

with BM-MSC conditioned medium had increased abundance of macrophages, suggesting that factors released by BM-MSCs recruit macrophages and endothelial lineage cells into the wound, thus improving wound healing.

Macrophages can phenotypically change from pro-inflammatory (M1) to anti-inflammatory (M2) state (QING, 2017) by the influence of MSCs. Studies has demonstrated that MSCs can “educate” these cells to activate into the anti-inflammatory state. *In vitro*, after co-culture with MSCs, macrophages assumed an immunophenotype defined as IL-10 high, IL-12 low, IL-6 high and TNF- $\alpha$  low secreting cells, with a potentially significant role in tissue repair (KIM; HEMATTI, 2009). An *in vivo* experiment, demonstrated that systemically infused MSCs could interact with host macrophages at wound site, and promote them toward M2 polarization, attenuating local inflammation mediated by a suppressed infiltration of inflammatory cells and production of IL-6 and TNF- $\alpha$ , and an increased expression of IL-10 (ZHANG et al., 2010).

Analyzing wound repair phases, studies demonstrated influence of MSCs. Enhanced re-epithelization, reduced inflammatory infiltration and increased collagen deposition was observed by Pelizzo et al. (2015) in wounds treated with ASCs in rabbits. In dogs, collagen deposition, cellular proliferation and angiogenesis was also increased by BM-MSC (KIM et al., 2013b).

The use of cell therapy in normal wound is important to elucidate their roles in wound repair and to characterize their actions on wound repair phases. Moreover, repair of chronic wounds was also shown to be improved by this treatment. Diabetic foot ulcer, for example, is one of the most frequent reasons for hospitalization and may lead to amputation, despite of current standards of care (FRYKBERG et al., 2006). BM-MSC seeded in collagen provided increasing wound closure and angiogenesis in rabbit diabetic ulcer, showing another strategy for non-healing diabetic foot ulcer (O’LOUGHLIN et al., 2013).

The role of MSCs in wound healing can be upgraded by scaffolds. Two dimensional mono-layers is widely regarded as poorly efficient, evidenced by the low rate of survival of MSCs at the site of injury (YANG et al., 2017). When analyzed *in vitro*, the association of MSCs and fibrin glue improved the paracrine effect of these cells by increasing secretion of VEGF, (TGF)-b1 and

prostaglandin E2 under inflammatory conditions. Fibrin glue as scaffold also provide cell adhesion in the wound site and migration away from the inferior border of the fibrin matrix, interacting with cells of the host dermis (ZEBARDAST; LICKORISH; DAVIES, 2010) and sustained cell survival, protecting them from oxidative stress (KIM et al., 2013a). *In vivo* experiment using platelet poor plasma associated with amnion, grafted with MSCs, showed improvement in wound healing and growth factors expression, compared with wounds treated with MSCs alone and control in rats (YANG et al., 2017).

## CONCLUSIONS

Wound healing is a well-known process. Many components play a role in wound healing, each one with their functions combined to orchestrate a successful repair. However, several conditions can influence in the process, delaying wound repair mostly by perpetuating inflammatory phase, and thus, rendering new treatment options.

MSC-based therapy is emerging as a promising option, able to promote wound healing in chronic wounds. Their paracrine effect is the major mechanism that influence the results and further researches are needed to clarify how they interact with resident cells, circulating cells, and extracellular matrix, so that a suitable, efficient and safe technique may be available for clinical trials.

**CHAPTER II****Adipose tissue-derived mesenchymal stromal cells associated with  
platelet poor plasma for cutaneous wound healing**

Fernanda Campos Hertel et al.

## **Adipose tissue-derived mesenchymal stromal cells associated with platelet-poor plasma for cutaneous wound healing**

### **ABSTRACT**

The difficulty of repairing chronic wounds is common and became a global issue with large financial costs, leading researchers to aim for novel treatments, with regenerative medicine and tissue engineering being the primary focus. In this context, MSCs become a potential therapy for wound healing. Thus, we sought to investigate the influence of adipose tissue-derived mesenchymal stromal cells (ASCs) on wound repair and the use of platelet poor plasma (PPP), an autologous fibrin network, as a temporary matrix to improve ASCs adhesion to the wound site. To this end, full thickness skin defects of 8mm-diameter were created on the dorsum of healthy rabbits. Next, defects were treated according to three groups: control, PPP only and PPP associated to allogenic ASCs. For macroscopic assessment in day 0, 7 and 14, digital photographs were taken from the wounds. Biopsies were performed at 14 days for confocal microscopy to analyze cell adhesion and survival and for routine histopathological analysis. Our results showed that ASCs associated with PPP remained in the wound until day 14, and were able to improve wound epithelization and wound closure until day 7. Histological analysis revealed that ASCs may have increased cellular infiltrate in later stage of proliferation, and PPP group showed an advanced granulation tissue maturation, compared to ASC+PPP and control group through its fibrin network without ASCs influence.

**Keywords:** cell therapy; regenerative medicine; scaffold; skin; tissue engineering.

## INTRODUCTION

As well known, wound healing is a multi-orchestrated process with overlapping phases, named hemostasis/inflammation, proliferation, and remodeling (LINDLEY et al., 2016). These are driven by biological and molecular events occurring under the influence of cells, cytokines, growth factors and the extracellular matrix., which can be negatively or positively influenced by local and systemic factors (BEHM et al., 2012). New treatments today aim at improving regeneration of the skin in wounds with complicating factors such as extensive and/or deep wounds, as well as systemic complication ones, like malnutrition and diabetes, thus, preventing scar formation (HAYASHIDA et al., 2016). Among them, improving the regeneration process are the use of mesenchymal stromal cells (MSCs) (SCHREML et al., 2010).

The influence of MSCs in wound healing comes from its paracrine activity. The secretion of several cytokines and growth factors is believed to be the source of their therapeutic effect (GNECCHI et al., 2008). The potential therapeutic mechanisms mediated by MSCs extend from cytoprotecting, tissue repair (anti-apoptotic and pro-mitotic), and neovascularization, in addition to the anti-inflammatory effect (GNECCHI et al., 2016). These mechanisms can be affected by the local microenvironment, cell culture conditions and cell delivery (YANG et al., 2017).

When MCSs are directly implanted into defects, they have limited retention and survival, therefore numerous studies are trying to prevent cell loss with a suitable carrier (KIM et al., 2013a; WU; REN; LI, 2012). Fibrin networks are potential temporary matrix to provide cell adhesion (HATAKEYAMA et al., 2014), and fibrin glue has shown potential as cell-delivery improving the therapeutic effect of MSCs, sustaining survival and migration (ZEBARDAST et al., 2010) and their paracrine function (KIM et al., 2013a).

Autologous matrices, such as platelet rich plasma, have been studied in association with MSCs (LIAN et al., 2014; ARGOLO NETO et al., 2016; HOSNI AHMED et al., 2017). Platelet-poor plasma is present in fewer studies, mainly due to the fact that it does not present significant amount of growth

factors (HATAKEYAMA et al., 2014), however it has an important fibrin network, which have potentially led to promising results in some studies (TAJIMA et al., 2007; YANG et al., 2017).

Adipose tissue derived mesenchymal stromal cells (ASCs) has been shown to promote tissue repair in several studies (MIZUNO, 2009; ZUK, 2013), including cartilage (WEI et al., 2009), bone (CIUFFI; BRANDI; PIERACCINI, 2017) and skin (NIE et al., 2011). These cells are easily harvested and expanded, since adipose tissue represents an abundant stem cell source, presenting a frequency of MSCs around 1 in 100 cells, about 500 times more than in the bone marrow, the more common source of MSC (FRASER et al., 2006). Also, it is associated to less donor site morbidity (KERN et al., 2006).

In this study, we aimed at evaluating the effect of allogenic ASC's associated with platelet poor plasma (PPP) as a scaffold in cutaneous wounds.

## **METHODS**

Experiments were performed at the Universidade Federal de Viçosa (UFV, Brazil) with approval of the Ethics Committee on Animal Use of the UFV (CEUA/UFV), as certified in case number 05/2018.

### **Adipose tissue harvest**

One young female New Zealand rabbit (6 months old, 3.5 kg weight) was used for adipose tissue harvest. After premedication with an intramuscular midazolam (1 mg/kg) and ketamine (12,5 mg/kg) injection, induction and general anesthesia was performed with isoflurane diluted in 100% oxygen. A linear incision was made in the interscapular area, and adipose tissue was collected into 50 ml sterile phosphate-buffered saline (PBS). The subcutaneous closure was made with polyglactin 3-0 and the wound sutured with nylon 3-0. Analgesia was performed with tramadol hydrochloride (6 mg/kg/IM) for two days.

### **Isolation of adipose derived MSCs (ASCs)**

In laminar flow cabinet using sterile technique, the fragments of adipose tissue were dried using filter paper (Fig 1A) and then chopped with a scalpel on a petri dish (Fig 1B). Then, slices were digested with type I collagenase (2 mg/ml, Sigma-Aldrich) in Dulbecco's modified Eagle Medium (DMEM, Gibco, Invitrogen) for 3h at 37°C, adapted from Semyari et al. (2015) (figures 1C and 1D). After digestion the flasks were centrifuged and the pellet transferred into T25 flask containing 5 ml of culture media (74.2% high glucose DMEM + 15% fetal bovine serum + 10% antibiotic solution + 0.4% essential amino acids + 0.4% L-glutamine) at 37°C, 5% of CO<sub>2</sub> until reach 80-90% of confluence. Culture media was refreshed every 2 or 3 days. Once the confluence was reached, cells were trypsinized using 0.25% heat-treated trypsin-EDTA, and were plated into 75 cm<sup>2</sup> flasks. Cells were culture until passage two.

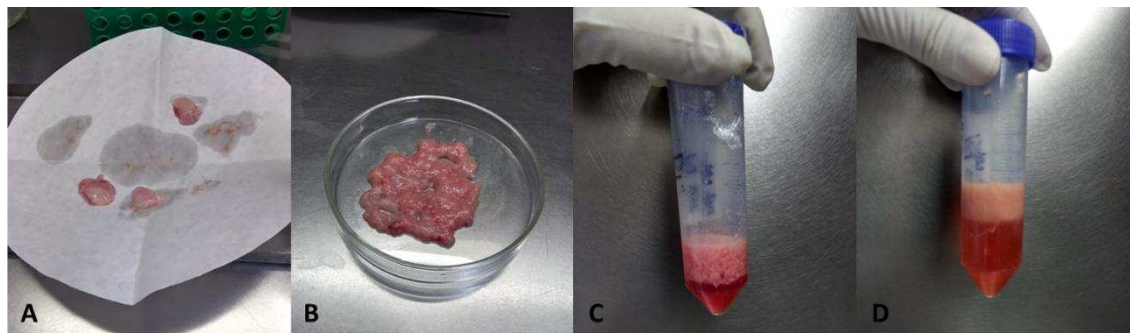


Figure 1: Isolation process of adipose-derived MSC. A, interscapular adipose tissue drying in filter paper. B, adipose tissue appearance after slicing. C, adipose tissue in collagenase suspension. D, adipose tissue appearance after digestion.

### Cell labelling

Prior to transplantation, cells were stained with PKH26 membrane dye (MINI26-1KT, Sigma-Aldrich) according to manufacturer's instructions. Briefly,  $1 \times 10^7$  cells were trypsinized using 0.25% heat-treated trypsin-EDTA, washed with PBS and suspended in 2ml of diluent C and 40  $\mu$ l of ETOH, obtaining  $5 \times 10^6$ /ml. After 3 minutes in room temperature, 2 ml of SFB were added, then after centrifugation, the pellet was washed twice with PBS. The pellet was transported within DMEM medium until transplantation.

### Preparation of PPP

After premedication with intramuscular midazolam (1 mg/kg) and ketamine (12,5 mg/kg) injection, general anesthesia with isoflurane diluted in 100% oxygen, 5 ml of blood was collected into a sodium citrate tube from each animal for autologous use. The samples were centrifuged at 700 g for 8 minutes, and the upper layers, were transferred to a new centrifuge tube, without any chemical additives. Another centrifugation was performed at 1600 g for 8 min, then 2/3 of it were collected from the upper layer as PPP. At the moment of application, PPP of each animal was activated with 0,3 ml of 2% calcium chloride (adapted from HATAKEYAMA et al., 2014).

### **Rabbit cutaneous wound model**

Healthy, mixed gender, New Zealand rabbits (n=18) weighing on average 3,5 kg and 6 months aged were used as animal model of skin wounds.

Under general anesthesia, as described above, two identical full thickness wounds were created on the back of each rabbit using an 8 mm circular punch, at a distance of 2 cm from each other. One lesion was used for histopathological and histomorphometry analysis and the other was set aside for future RT-qPCR analysis.

Animals were separated in three experimental groups (6 animals each) according to the treatment: control (CO), platelet-poor plasma (PPP) and ASCs associated with PPP (ASC+PPP). For allogenic transplantation, a suspension with  $2,5 \times 10^6$  cells (stained or not) in 1ml of activated PPP was prepared for each wound (figure 2), and the suspension was deposited directly onto the wounds in ASC+PPP group (figure 3A and 3B) using a 3ml syringe. For CO group, 1 ml of saline solution was deposited onto the wounds and for PPP group, 1 ml was prepared for each animal, activated and deposited onto the wounds.

After filling the defects, each wound was covered with gauze with petrolatum emulsion, then with transparent film dressing (figure 3C and 3D). Analgesia was performed with tramadol hydrochloride (6 mg/kg/IM) for two days.

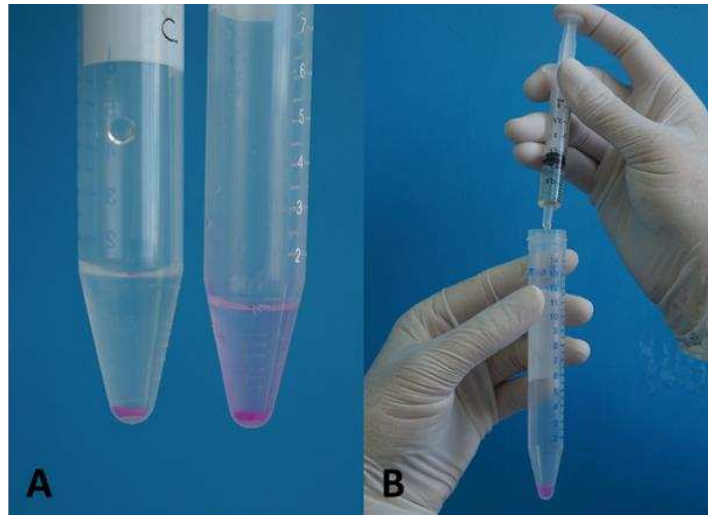


Figure 2: A, ASCs pellet in PBS, stained with membrane dye. B, preparing PPP suspension with stained cells before application.

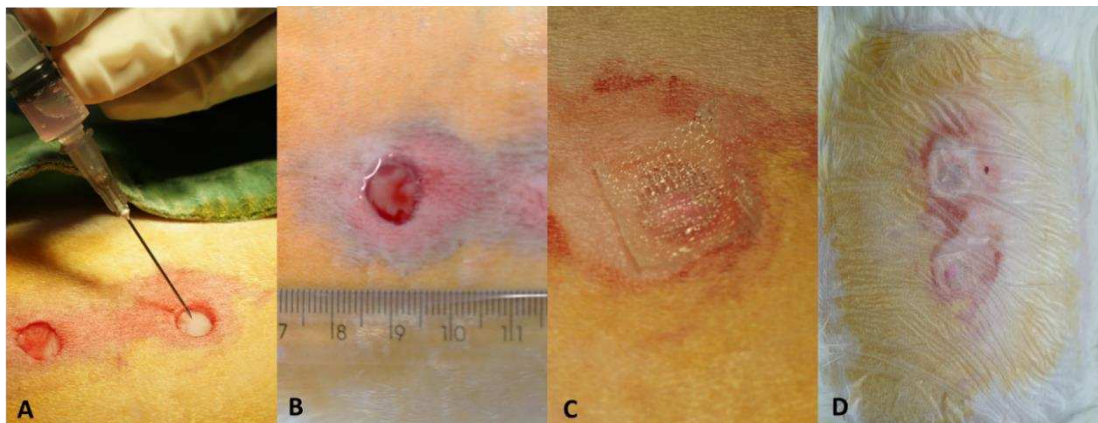


Figure 3: Wound preparation. A, application of ACSs suspension in PPP. B, PPP gel in the wound. C, gauze with petrolatum covering the wound. D, transparent film dressing.

### Clinical evaluation

The wound dressing was changed every day, until day 7. Then, the wound was let open. Wound closure was documented daily with photographs, using a ruler as measurement reference, positioned near the wound. Using the ImageJ software, the percentage of wound contraction, wound epithelialization and the percentage of wound healing, was calculated with formulas according to Mehrjerdi et al. (2008), described below, at day 7 and 14. For this, the day

of wound creation was considered day zero. Reepithelization area was characterized by a thinner and brighter tissue compared to the uninjured skin.

- Wound contraction:

- a)  $\text{Wound size at the day (x) cm}^2 / \text{wound size at the day (0) cm}^2 \times 100 =$  percent of the wound size at the day (x)
- b)  $100 - \text{percent of wound size at day (x)} = \text{percent of wound contraction}$

- Wound epithelialization:

- a)  $\text{Size of epithelialization area (wound size at day x} - \text{granulation area) at the day (x) cm}^2 / \text{size of the wound at the day (x) cm}^2 \times 100 =$  percent of the epithelialization

- Wound healing:

- a)  $\text{Granulation tissue at the day (x) cm}^2 / \text{wound size at the day (0) cm}^2 \times 100 =$  percent of the non-healed area to compare of the wound size at the day (0)
- b)  $100 - \text{percent of the non-healed area to compare of the wound size at the day (0)} = \text{percent of the healing.}$

### **Histopathological and histomorphometry analysis**

Biopsies were taken at day 14 for histopathological and histomorphometry examination.

After premedication with an intramuscular midazolam (1 mg/kg) and ketamine (12,5 mg/kg) injection, the animals were maintained in general anesthesia with isoflurane diluted in 100% oxygen. Blockage by subcutaneous infiltration of lidocaine 2% (7mg/kg) were performed around the wounds, and an elliptic incision were made around the wound area, respecting 0,5 cm of edge. The subcutaneous were sutured with 3-0 polyglycolic acid, and the skin were closed using 3-0 nylon. Analgesia was performed using tramadol hydrochloride (6 mg/kg/IM) for two days.

The wound specimens were fixed in 10% buffer formalin and embedded in paraffin. Samples from the PPP+ASCs groups were first immersed into PBS and analyzed by confocal microscopy (LSM 510 META, Zeiss, Germany) to access cell adhesion and survival. Samples were stained using hematoxylin-eosin and picosirius red. Inflammatory infiltrate, fibroblast

proliferation, and angiogenesis were scored as follows: absent: 0, mild:1, moderate: 2 and marked: 3 in each sample. Blinded analysis was performed separately by 2 experienced dermatopathologists.

For collagen analysis, all sections were examined with an optical microscope under polarized light (Olympus BX-53 ®, Japan). With a coupled digital camera (5.0m), 10 histological fields were selected for each slide at 40x magnification. The images were analyzed using ImageJ software, with the plug-in Threshold Color, obtaining the percentage of collagen through the analysis of automated particles according to the selection and measurement of areas based on color.

### **Statistical analysis**

Macroscopic variables were evaluated by the one-way ANOVA and the histomorphometry data were evaluated by the Kruskal-Wallis, both followed by the Tukey test, in case of significance ( $P < 0,05$ ). For both, analysis consisted on the comparison between groups.

## **RESULTS**

### **Cell delivery and survival**

Tissue analysis by confocal microscopy showed a sustained presence of ASCs in all defects, 14 days after labelling and application. Fluorescent cells were observed mostly in the wound surface, presenting in aggregates or isolated cells (figure 4).

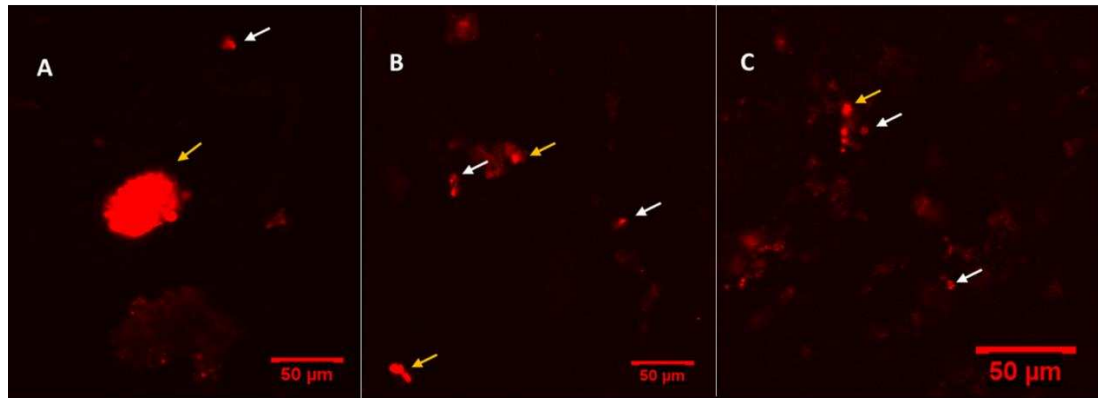


Figure 4: Images by confocal microscopy 14 days after transplantation of rabbits' ASCs stained membrane dye, applied onto skin wound. Yellow Arrows: ASCs aggregates. White arrows: isolated ASCs.

### Assessment of the healing process

All the animals recovered well after surgery, and wounds healed without complications (figure 5).

At day 7, ASC+PPP group showed a faster epithelialization (47.2%) compared to control (32.3%) and PPP group (35.5%) ( $P < 0.05$ ) (figure 6). Also in day 7, the percentage of wound healing was higher in ASC+PPP (58.4%) in comparison with control group (43.3%) (figures 5 and 6). At day 14 no significant difference was observed. The percentage of wound contraction was not different between groups, although it exhibited a tendency to be higher in PPP group at day 7 (29.6%) and day 14 (69.35%) compared with control (15.63% at day 7, and 57.4% at day 14) and ASC+PPP (21.3% at day 7, and 63.4% at day 14) groups.

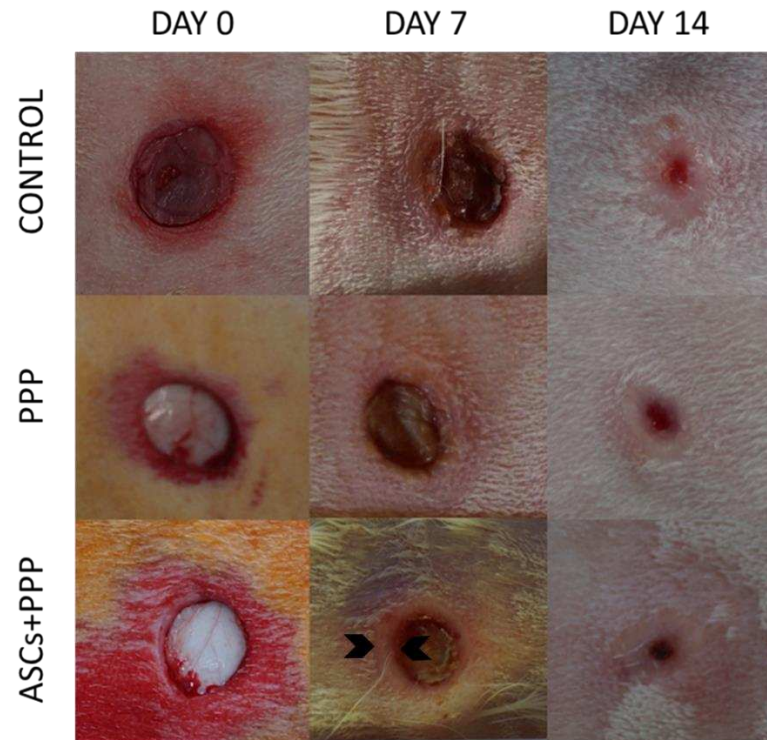


Figure 5: wound healing process at day 0,7 and 14. Notice the evident epithelization halo in day 7 of ASCs+PPP group (arrow heads).

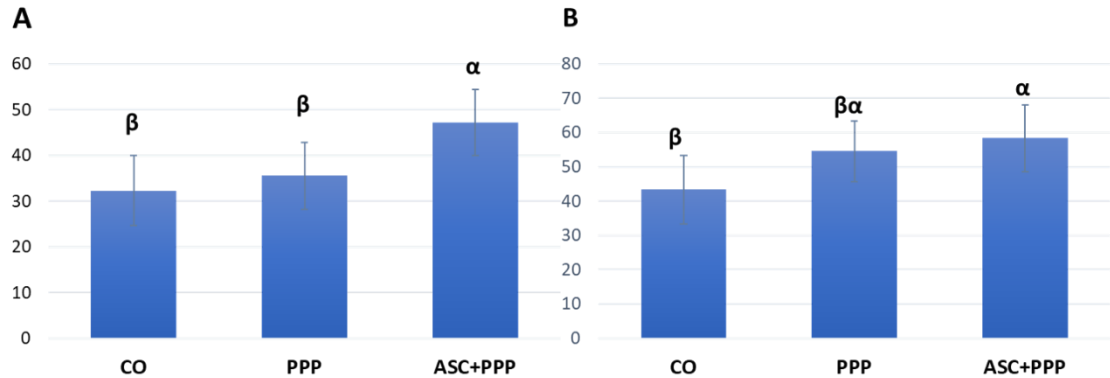


Figure 6: A, Percentage of epithelialization at day 7 (A). Wound healing percentage in day 7 (B). Error bars represent standard deviation from the mean. Different symbols differ statistically ( $P < 0,05$ ).

### Histopathological and histomorphometry analysis

Cellular infiltrate was markedly more intense in the ASC+PPP group, characterized by a mixed infiltrate in all groups, however the presence of eosinophils was evident within this infiltrate, markedly in the group treated with ASCs. Fibroblasts and vascular proliferation were more intense in control

group. A similar rate of proliferation of fibroblasts and vessels was observed in PPP and ASC+PPP groups. Collagen fiber organization was also evaluated, and showed that, in PPP and control groups, more fibers were disposed parallel to the epidermis compared to ASC+PPP group (figure 7).

In histomorphometry, the amount of collagen type III (green) and collagen type I (red) deposition and their proportion showed no significant difference between groups (figure 8).

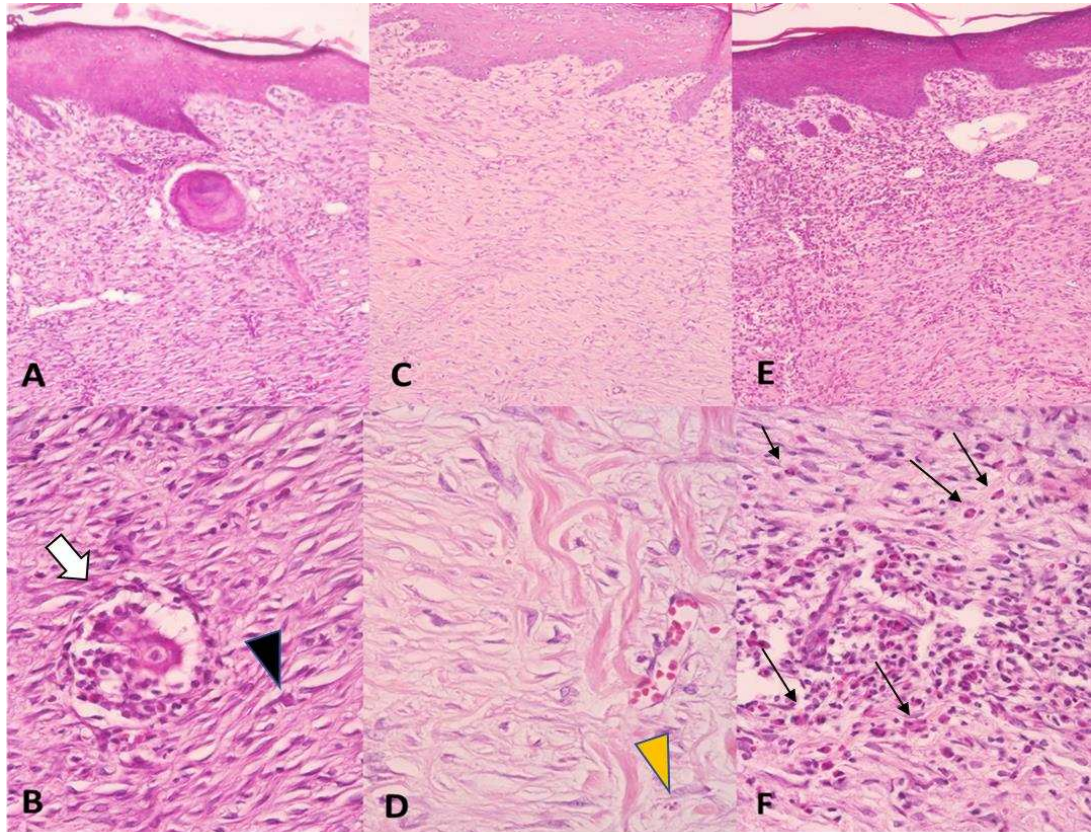


Figure 7: Histopathologic sections of rabbit cutaneous wound in day 14, stained with HE. A, control group, moderate fibroplasia and inflammatory infiltrate, 100x, B, image of the same case in A, exhibiting another field with a giant cell within fibroblasts (white arrow), and less presence of eosinophils (black arrow head) 400x. C, PPP group, lower inflammatory infiltrate, 100x. D, same case in C, in evidence lower fibroblasts density and thicker collagen fibers, also lower number of eosinophils (yellow arrow head) 400x. E, ASC+PPP group, intense cellular infiltrate in the interface of dermis and epidermis, 100x. F, same case in E, evidencing the inflammatory cells with eosinophils (black arrows), 400x.

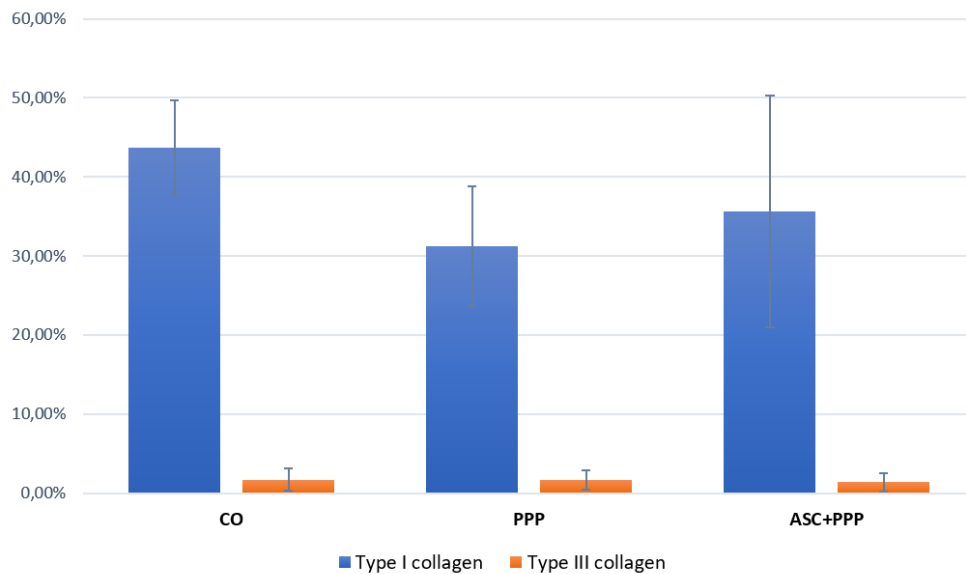


Figure 8. Percentage of collagen type I and III at 14 days of healing of skin wounds.

## DISCUSSION

The skin is the largest organ of the human body and it has multiple functions in maintaining homeostasis. Wound healing is often a great challenge mainly due to extensive loss of skin and co-morbid clinical conditions, requiring different modalities of treatment to obtain an adequate healing (ENNIS; SUI; BARTHOLOMEW, 2013). The overlapping phases of wound healing – inflammation, proliferation and remodeling – are orchestrated by controlled biological and molecular events, with growth factors, cytokines, cells and extracellular matrix being the major components (BEHM et al., 2012). The transition from inflammatory to the proliferative phase is crucial for wound healing, and chronic inflammation is one of the hallmarks of a chronic nonhealing wound (ENNIS; SUI; BARTHOLOMEW, 2013).

MSCs came to the scenery of wound healing for its paracrine effect, being able to secrete several cytokines and growth factors, leading to the therapeutic effect of these cells (GNECCHI et al., 2008). However, adequate adhesion and prolonged survival is still a challenge (KIM et al., 2013a). We showed that ASCs remained in the wound site until 14 days, when wounds were almost closed, suggesting PPP was successful to promote survival and adhesion of these cells. Similarly, O’Loughlin et al. (2013) reported the

presence of MSCs labelled with the same membrane dye we used until day 7 of wound healing, using a collagen scaffold in a diabetic rabbit ulcer model. However, not all scaffolds behave the same in different environments. While Kim et al. (2013a), observed poor migration of MSCs in fibrin glue *in vitro*, Zebardast et al, (2010) observed human umbilical cord perivascular cells migration from the fibrin glue to the wound area. Interestingly, we observed the fluorescent cells mostly in wound surface, especially in the interface of epidermis and dermis, a finding also observed by Zebardast et al, (2010).

Our results demonstrated that ASCs associated with PPP were able to accelerate epithelization, which may have reflected on the improved wound healing in the beginning of the process, observed by the earlier transition from inflammatory to proliferative phase in the macroscopic analysis (figure 5). Enhanced epithelization was also observed in early phases using autologous ASCs by intradermal inoculation in rabbits cutaneous wound (PELIZZO et al., 2015), and Mehanna et al. (2015) reported that MSCs in fibrin vehicle could improve the quality of healed skin in chronic wounds in rats, albeit without true acceleration of wound closure. The therapeutic effect of MSCs in wound healing was also observed by Yang et al. (2017), using PPP associated with amniotic fluid as carrier. They showed that this carrier can modify growth factor expression levels of human umbilical cord derived MSCs and improve their efficiency in the healing of full thickness wounds in rats. The mechanisms by which ASCs accelerate epithelization and improve the rate of wound size decrease were clarified in animal models with conditioned medium, proved to be due to the effect of PDGF, IGF, and KGF (EBRAHIMIAN et al., 2009; KIM et al., 2007; KIM; PARK; SUNG, 2009; NIE et al., 2011).

At day 14, a more intense cellular infiltrate in ASC+PPP group may indicate a paracrine effect of ASCs by stimulating polymorphonuclear and mononuclear cells migration to the wound site. Despite many of these cells behave as pro-inflammatory in the early stage of wound healing, in later stages they can modulate the inflammatory response (YOUSUF; AMINI NIK, 2017). For instance, neutrophils secrete growth factors and cytokines that promote the proliferation of fibroblasts, keratinocytes, and endothelial cells (LAROUCHE et al., 2018) and in later stages undergo apoptosis and are engulfed by macrophages causing them to reprogram into an anti-

inflammatory phenotype (LUCAS et al., 2003). This phenotype, known as M2, act in the proliferative/remodeling stage secreting VEGF, IGF-1 and IL-10 (BRANCATO; ALBINA, 2011). The marked presence of eosinophils in ASC+PPP group suggest an important influence of ASCs recruiting these cells into the wound site and improving epithelization, observed in day 7. Todd et al. (1991) showed that eosinophil is the predominant cell type in rabbit cutaneous wounds and increases progressively during healing and remains high in the granulation tissue even after epithelial closure. Also, eosinophils are a source of TGF- $\alpha$  and  $\beta$ 1 (TODD et al., 1991), the first acting as mitogenic and chemotactic for keratinocytes and fibroblasts (SPACCAPELO, 2016) and the second is important for matrix remodeling and angiogenesis by inducing the expression of MMP-9 (LAMAR; IYER; DIPERSIO, 2008).

It is important to notice that the ASCs was found predominantly on wound surface using confocal microscopy. Also, the cellular infiltrate observed in histological analysis of ASC+PPP group were localized more intensively in the interface of epidermis and dermis. Zebardast et al. (2010) also observed the predominance of umbilical cord perivascular cells in this location. Therefore, we must considerer that part of this cellular infiltrate may be the implanted ASCs, not just inflammatory cells, once were deposited  $2,5 \times 10^6$  cells per defect.

As the proliferation phase advances, collagen deposition increases and fibroblasts proliferation diminishes, also in the remodeling phase the wound blood flow declines (REINKE; SORG, 2012). Thus, PPP group showed a more mature wound compared with control and ASC+PPP groups at 14 days, once collagen fibers in the first were more aligned to the skin surface than the other ones. More fibroblasts and vessels were present in control group, indicating a less mature wound.

PPP is a fibrin-rich plasma, with a higher amount of fibrinogen and fewer platelets, about 30-fold less concentration of PDGF-AB, and 5-fold less concentration of TGF- $\beta$ 1 compared to other blood derived, as platelet-rich fibrin (PRF), and platelet-rich plasma (PRP). The fibrin present in PPP works as a temporary matrix for cellular adhesion and migration, what may have influenced the more advanced maturation in PPP group compared to control. A similar result was demonstrated in osteogenic formation, when PPP alone

showed an enhanced bone formation in extraction sockets in dogs, than PRP and PRF groups (HATAKEYAMA et al., 2014). However, considering that PPP improved maturation also in comparison to ASC+PPP group, it should be considered the intense presence of eosinophil in this last group, as it is known that cells, growth factors can cytokines can act in different ways according to the stimuli and wound phase (LUCAS et al., 2003; LAROUCHE et al., 2018). There aren't many studies analyzing the role of eosinophil in wound healing, therefore, further studies are needed to elucidate the mechanisms and the moments which eosinophils act, and if the MSCs presence could perpetuate their action in the process.

Histological staining by picrosirius red is the most commonly used method to evaluate the presence of collagen fibers (RIBEIRO et al., 2015). However, they are characterized as thin and thick fibers, but are commonly assigned as collagen type I (thicker) with a strong yellow-red birefringence and collagen type III (thinner) with a weak birefringence associated with a greenish color (MONTES; JUNQUEIRA, 1991). In the proliferative phase, type III collagen deposition occurs and in the maturation phase, type III collagen is replaced by type I (RIBEIRO et al., 2015). Our analysis demonstrated a higher amount of type I collagen deposition in all groups compared to type III collagen, without significant differences between treatments. This finding indicates that the treatments became similar in the maturation phase, in relation to collagen deposition.

In summary, ASCs improved epithelization in the transition of inflammatory to proliferative phase, however, the association with histopathologic, histomorphometry and macroscopic analysis showed that differences in day 14 were minimal, and subject to further analysis. Limitations of our study relay mainly on the absence of histological analysis at day 7, when the most prominent differences were observed. Molecular analyses of growth factors and cytokines expression could also clarify the mechanisms which ASCs influence in the wound and immunohistochemistry to identify the predominant cell type.

This work in normal skin wounds is the first step to characterize this treatment option, enabling further assessment for the treatment for skin wounds with local and systemic complications.

## **CONCLUSIONS**

ASCs improved epithelization in the transition of inflammatory to proliferative phase, although did not improve granulation tissue maturation in comparison to PPP treated group. PPP may improve wound maturation and were successful for delivering ASCs. ASCs also recruited eosinophils to the wound site, and this process require further analysis.

## **ACKNOWLEDGMENTS**

The authors would like to thank CAPES (Finance Code 001), FAPEMIG and CNPq for financial support. Also, the Nucleus of Microscopy and Microanalysis (NMM-UFV) for support on confocal microscopy and the Labtec (Department of Animal Science) for providing the cell culture laboratory.

## GENERAL CONCLUSIONS

Clearly, MSCs are able to influence the wound healing outcome, due to their paracrine effect, secreting several growth factors and cytokines capable of stimulating resident and circulating cells and influence the extracellular matrix. Molecular events in wound healing, by MSCs influence, need elucidation, so we can understand exactly by which mechanisms these cells act.

In this study we showed that ASCs with PPP remained in the wounds, and improved epithelization. It also increased cellular infiltrate, especially eosinophils. We believe that ASC were able to stimulate these cells to secrete both growth factors and pro-inflammatory cytokines, playing two different roles in wound healing. Further studies are necessary to elucidate this behavior and molecular analysis should also help to clarify. These results enable us to safely analyze the therapy use of ASC+PPP in chronic, impaired or extensive wounds, in which we expect their remarkable effect improving wound healing.

## REFERENCES

- ACHAR, R. A. N. et al. Use of insulin-like growth factor in the healing of open wounds in diabetic and non-diabetic rats. **Acta Cirurgica Brasileira**, v. 29, p. 125-131, 2014.
- ARGOLO NETO, N. M. et al. Role of the autologous mesenchymal stem cells compared with platelet rich plasma on cicatrization of cutaneous wounds in diabetic mice. **Pesquisa Veterinária Brasileira scielo**, v. 36, n. 7, p. 617-624, 2016.
- BAINBRIDGE, P. Wound healing and the role of fibroblasts. **Journal of wound care**, v. 22, n. 8, p. 407–412, 2013.
- BALBINO, C. A.; PEREIRA, L. M.; CURI, R. Mecanismos envolvidos na cicatrização: uma revisão. **Revista Brasileira de Ciências Farmacêuticas**, v. 41, n. 1, p. 27–51, 2005.
- BARRIENTOS, S. et al. Clinical Application of Growth Factors and Cytokines in Wound Healing. **Wound Repair Regen**, v. 22, n. 5, p. 569–578, 2016.
- BEHM, B. et al. Cytokines, chemokines and growth factors in wound healing. **Journal of the European Academy of Dermatology and Venereology**, v. 26, p. 812–820, 2012.
- BENNETT, N. T.; SEHULTZ, G. S. Growth Factors and Wound Healing : Part II . Role in Normal and Chronic Wound Healing. **The american journal of surgery**, v. 166, p. 728–37, 1993.
- BODNAR, R. J. Epidermal Growth Factor and Epidermal Growth Factor Receptor : The Yin and Yang in the Treatment of Cutaneous Wounds and Cancer. **Advances in Wound Care**, v. 2, n. 1, p. 24–29, 2013.
- BRANCATO, S. K.; ALBINA, J. E. Wound macrophages as key regulators of repair: origin, phenotype, and function. **The American journal of pathology**, v. 178, n. 1, p. 19–25, jan. 2011.
- BREM, H. et al. Molecular Markers in Patients with Chronic Wounds to Guide Surgical Debridement. **Molecular Medicine**, v. 13, n. 1–2, p. 30–39, 2007.
- BRUHN-OLSZEWSKA, B. et al. Molecular factors involved in the development of diabetic foot syndrome. **Acta Biochimica Polonica**, v. 59, n. 4, p. 507–513, 2012.
- CHEN, L. et al. Paracrine factors of mesenchymal stem cells recruit macrophages and endothelial lineage cells and enhance wound healing. **PLoS One**, v. 3, n. 4, 2008.
- CIUFFI, S.; BRANDI, M. L.; PIERACCINI, V. Adipose stem cells for bone tissue repair. **Clinical Cases in Mineral and Bone Metabolism**, v. 14, n. 2, p. 217–

226, 2017.

CORNICK, S. MAC et al. Clinical Use of Growth Factors in the Improvement of Skin Wound Healing. **Open Journal of Clinical Diagnostics**, v. 4, p. 227–236, 2014.

DA ROSA SILVA, C. F. et al. High prevalence of skin and wound care of hospitalized elderly in Brazil: a prospective observational study. **BMC research notes**, v. 10, n. 1, p. 81, 2 fev. 2017.

DARBY, I. A. et al. Fibroblasts and myofibroblasts in wound healing. **Clinical, Cosmetic and Investigational Dermatology**, v. 7, p. 301–311, nov. 2014.

DINH, T.; BRAUNAGEL, S.; ROSENBLUM, B. I. Growth Factors in Wound Healing: The Present and the Future? **Clinics in Podiatric Medicine and Surgery**, v. 32, n. 1, p. 109–119, 2015.

EBRAHIMIAN, T. G. et al. Cell Therapy Based on Adipose Tissue-Derived Stromal Cells Promotes Physiological and Pathological Wound Healing. **Arteriosclerosis, Thrombosis, and Vascular Biology**, v. 29, n. 4, p. 503–510, 1 abr. 2009.

ENNIS, W. J.; SUI, A.; BARTHOLOMEW, A. Stem Cells and Healing: Impact on Inflammation. **Advances in Wound Care**, v. 2, n. 7, p. 369–378, 2013.

FONDER, M. A. et al. Treating the chronic wound: A practical approach to the care of nonhealing wounds and wound care dressings. **Journal of the American Academy of Dermatology**, v. 58, n. 2, p. 185–206, 2008.

FRYKBERG, R. G. et al. Diabetic Foot Disorders: A Clinical Practice Guideline (2006 Revision). **The Journal of Foot and Ankle Surgery**, v. 45, n. 5, p. S1–S66, 2006.

GNECCHI, M. et al. Paracrine Mechanisms in Adult Stem Cell Signaling and Therapy. **Circulation Research**, v. 103, n. 11, p. 1204–1219, 2008.

GOWDA, S. et al. Topical application of recombinant platelet-derived growth factor increases the rate of healing and the level of proteins that regulate this response. **International Wound Journal**, v. 12, p. 564-71, 2013.

HATAKEYAMA, I. et al. Effects of Platelet-Poor Plasma, Platelet-Rich Plasma, and Platelet-Rich Fibrin on Healing of Extraction Sockets with Buccal Dehiscence in Dogs. **Tissue Engineering Part A**, v. 20, n. 3, p. 874–882, 2014.

HAYASHIDA, K. et al. Effectiveness of basic fibroblast growth factor for pediatric hand burns. **Journal of Tissue Viability**, v. 25, n. 4, p. 220–224, 2016.

HELDIN, C.; WESTERMARK, B. Mechanism of Action and In Vivo Role of Platelet-Derived Growth Factor. **Physiological Reviews**, v. 79, n. 4, p. 1283–1316, 1999.

HOSNI AHMED, H. et al. Can mesenchymal stem cells pretreated with platelet-rich plasma modulate tissue remodeling in a rat with burned skin? **Biochemistry and Cell Biology**, v. 95, n. 5, p. 537–548, 17 mar. 2017.

HU, Y. et al. The Role of Interleukin-1 in Wound Biology. Part II: In Vivo and Human Translational Studies. **Anesthesia Analgesia**, v. 111, n. 6, p. 1534–1542, 2010.

HYNES, R. O. Extracellular matrix: not just pretty fibrils. **Science**, v. 326, n. 5957, p. 1216–1219, 2009.

ISHIDA, Y. et al. Absence of IL-1 Receptor Antagonist Impaired Wound Healing along with Aberrant NF- $\kappa$ B Activation and a Reciprocal Suppression of TGF- $\beta$  Signal Pathway. **The Journal of Immunology**, v. 176, n. 9, p. 5598 LP-5606, maio 2006.

JOHNSON, K. E.; WILGUS, T. A. Vascular Endothelial Growth Factor and Angiogenesis in the Regulation of Cutaneous Wound Repair. **Advances in Wound Care**, v. 3, n. 10, p. 647–661, out. 2014.

KANJI, S.; DAS, H. Advances of Stem Cell Therapeutics in Cutaneous Wound Healing and Regeneration. **Mediators of Inflammation**, v. 2017, p. 14 pages, 2017.

KERN, S. et al. Comparative Analysis of Mesenchymal Stem Cells from Bone Marrow, Umbilical Cord Blood, or Adipose Tissue. **Stem Cells**, v. 24, n. 5, p. 1294–1301, 1 maio 2006.

KIM, I. et al. Fibrin Glue Improves the Therapeutic Effect of MSCs by Sustaining Survival and Paracrine Function. **Tissue Engineering: Part A**, v. 19, n. 21–22, p. 2373–2381, 2013a.

KIM, J. et al. The effects of topical mesenchymal stem cell transplantation in canine experimental cutaneous wounds. **Veterinary Dermatology**, v. 24(2), p.242-e53, 2013b.

KIM, J.; HEMATTI, P. Mesenchymal stem cell-educated macrophages: a novel type of alternatively activated macrophages. **Experimental Hematology**, v. 37, n. 12, p. 1445–1453, 2009.

KIM, W.-S. et al. Wound healing effect of adipose-derived stem cells: A critical role of secretory factors on human dermal fibroblasts. **Journal of Dermatological Science**, v. 48, n. 1, p. 15–24, 1 out. 2007.

KIM, W.-S.; PARK, B.-S.; SUNG, J.-H. The wound-healing and antioxidant effects of adipose-derived stem cells. **Expert Opinion on Biological Therapy**, v. 9, n. 7, p. 879–887, 1 jul. 2009.

LAMAR, J.; IYER, V.; DIPERSIO, C. M. Integrin  $\alpha$ 3 $\beta$ 1 potentiates TGF $\beta$ -mediated induction of MMP-9 in immortalized keratinocytes. **The Journal of investigative dermatology**, v. 128, n. 3, p. 575–586, mar. 2008.

LAROUCHE, J. et al. Immune Regulation of Skin Wound Healing: Mechanisms and Novel Therapeutic Targets. **Advances in Wound Care**, v. 7, n. 7, p. 209–231, jul. 2018.

LEONOV, Y. I. et al. Effect of Insulin Like Growth Factor Transgene on Wound Healing in Mice with Streptozotocin Induced Diabetes. **Tsitologiya i Genetika**, v. 49, n. 1, p. 19–26, 2015.

LIAN, Z. et al. Synergistic effect of bone marrow-derived mesenchymal stem cells and platelet-rich plasma in streptozotocin-induced diabetic rats. **Annals of dermatology**, v. 26, n. 1, p. 1–10, fev. 2014.

LIN, C. et al. The effects of HIF-1 $\alpha$  and VEGF on wound healing in diabetic mice. **Biomedical Research**, v. 28, n. 18, p. 8121–8124, 2017.

LIN, Z. et al. Essential involvement of IL-6 in the skin wound-healing process as evidenced by delayed wound healing in IL-6-deficient mice. **Journal of Leukocyte Biology**, v. 73, p. 713–721, 2003.

LINDLEY, L. E. et al. Biology and Biomarkers for Wound Healing. **Plastic and reconstructive surgery**, v. 138, n. 3, p. 18–28, 2016.

LUCAS, M. et al. Apoptotic Cells and Innate Immune Stimuli Combine to Regulate Macrophage Cytokine Secretion. **The Journal of Immunology**, v. 171, n. 5, p. 2610 LP-2615, 1 set. 2003.

MARTINELLO, T. et al. Allogeneic mesenchymal stem cells improve the wound healing process of sheep skin. **BMC Veterinary Research**, v. 4:202 p. 1–9, 2018.

MASI, E. C. D. J. DE et al. The influence of growth factors on skin wound healing in rats. **Brazilian Journal of Otorhinolaryngology**, v. 82, n. 5, p. 512–521, 2016.

MCFARLAND-MANCINI, M. M. et al. Differences in Wound Healing in Mice with Deficiency of IL-6 versus IL-6 Receptor. **The Journal of Immunology**, v. 184, p. 7219–7228, 2010.

MEHANNA, R. A. et al. The Effect of Bone Marrow-Derived Mesenchymal Stem Cells and Their Conditioned Media Topically Delivered in Fibrin Glue on Chronic Wound Healing in Rats. **BioMed Research International**, v. 2015, p. 12 pages, 2015.

MEHRJERDI, H. K. et al. Efficacy of Autologous Platelet-Rich Plasma ( PRP ) Activated By Thromboplastin-D on the Repair and Regeneration of Wounds in Dogs. **Iranian Veterinary Surgery Association**, v. 3, n. 4, p. 19–30, 2008.

MIZUNO, H. Adipose-derived Stem Cells for Tissue Repair and Regeneration: Ten Years of Research and a Literature Review. **Journal of Nippon Medical School**, v. 76(2), p. 56-66, 2009.

MONTES, G. S.; JUNQUEIRA, L. C. U. The use of the Picrosirius-polarization

method for the study of the biopathology of collagen. **Memórias do Instituto Oswaldo Cruz**, v. 86, p. 1-11, 1991

NIE, C. et al. Locally administered Adipose-derived stem cells accelerate wound healing through differentiation and vasculogenesis. **Cell Transplantation**, v. 20, p. 205–216, 2011.

NIE, K. et al. Clinical observation of basic fibroblast growth factor combined with topical oxygen therapy in enhancing burn wound healing. **Chinese journal of reparative and reconstructive surgery**, v. 24, p. 643-646, 2010.

NIIYAMA, H.; KUROYANAGI, Y. Development of novel wound dressing composed of hyaluronic acid and collagen sponge containing epidermal growth factor and vitamin C derivative. **Journal of Artificial Organs**, v. 17, p. 81–87, 2014.

NUSCHKE, A. Activity of mesenchymal stem cells in therapies for chronic skin wound healing Activity of mesenchymal stem cells in therapies for chronic skin wound healing. **Organogenesis**, v. 10, n. 1, p. 29–37, 2014.

O'LOUGHLIN, A. et al. Topical administration of allogeneic mesenchymal stromal cells seeded in a collagen scaffold augments wound healing and increases angiogenesis in the diabetic rabbit ulcer. **Diabetes**, v. 62, n. 7, p. 2588–2594, 2013.

OJEH, N. et al. Stem Cells in Skin Regeneration, Wound Healing, and Their Clinical Applications. **International Journal of Molecular Sciences**, v. 16, p. 25476–25501, 2015.

PARK, S. A. et al. PDGF-BB does not accelerate healing in diabetic mice with splinted skin wounds. **PLoS One**, v. 9, n. 8, p. 24–27, 2014.

PASTAR, I. et al. Epithelialization in Wound Healing: A Comprehensive Review. **Advances in Wound Care**, v. 3, n. 7, p. 445–464, jul. 2014.

PELIZZO, G. et al. Mesenchymal stromal cells for cutaneous wound healing in a rabbit model : pre - clinical study applicable in the pediatric surgical setting. **Journal of Translational Medicine**, v. 13, n. 219, p. 1–14, 2015.

QING, C. The molecular biology in wound healing & non-healing wound. **Chinese Journal of Traumatology**, v. 20, n. 4, p. 189–193, 2017.

REINKE, J. M.; SORG, H. Wound Repair and Regeneration. **European Surgical Research**, v. 49, p. 35–43, 2012.

RIBEIRO, F. et al. Análise da concentração de colágeno tipo I e III presente no reparo de feridas tratadas com Mitomicina C em ratos. **Arquivos Médicos dos Hospitais e da Faculdade de Ciências Médicas da Santa Casa de São Paulo**, v. 60, n. 11, p. 22–26, 2015.

SATO, Y.; OHSHIMA, T.; KONDO, T. Regulatory Role of Endogenous Interleukin-10 in Cutaneous Inflammatory Response of Murine Wound Healing.

**Biochemical and Biophysical Research Communications**, v. 265, p. 194–199, 1999.

SCHREML, S. et al. Wound healing in the 21st century. **Journal of American Dermatology**, v. 63, n. 5, p. 866–881, 2010.

SEMYARI, H. et al. Isolation and Culture of Mesenchymal Stem Cells From Rabbit Scapular Subcutaneous Adipose Tissue and Their Ability to Differentiate Into osteoblasts. **journal of dental research**, v. 7, n. 2, p. 1–8, 2015.

SHI, J.-H. et al. Protection against TGF- $\beta$ 1-induced fibrosis effects of IL-10 on dermal fibroblasts and its potential therapeutics for the reduction of skin scarring. **Archives of Dermatological Research**, v. 305, n. 4, p. 341–352, 2013.

SHOHARA, R. et al. Mesenchymal stromal cells of human umbilical cord Wharton's jelly accelerate wound healing by paracrine mechanisms. **Cytotherapy**, v. 14, n. 10, p. 1171–1181, 2012.

SPACCAPELO, L. Rationale for basic FGF in wound healing and review of therapeutic applications. **European journal of Pharmaceutical and Medical Research**, v. 3, n. 5, p. 51–59, 2016

TAJIMA, N. et al. A three-dimensional cell-loading system using autologous plasma loaded into a porous  $\beta$ -tricalcium-phosphate block promotes bone formation at extraskeletal sites in rats. **Materials Science and Engineering C**, v. 27, n. 4, p. 625-632, 2007.

TODD, R. et al. The eosinophil as a cellular source of transforming growth factor alpha in healing cutaneous wounds. **The American journal of pathology**, v. 138, n. 6, p. 1307–1313, jun. 1991.

TRAVERSA, B.; SUSSMAN, G. The role of growth factors , cytokines and proteases in wound management. **Primary Intention**, v. 9, n. 4, p. 161–167, 2001.

UHL, E.; RÖSKEN, F.; SIRSJÖ, A.; MESSMER, K. Influence of platelet-derived growth factor on microcirculation during normal and impaired wound healing. **Wound Repair and Regeneration**, v.11, p. 361-367, 2003.

WANG, N. et al. E2F1 Hinders Skin Wound Healing by Repressing Vascular Endothelial Growth Factor (VEGF) Expression, Neovascularization, and Macrophage Recruitment. **PLoS One**, v. 11, n. 8, p. e0160411, ago. 2016.

WANG, P. et al. Wound healing. **Journal of the Chinese Medical Association**, v. 81, n. 2, p. 94–101, 2018.

WEI, Y. et al. Cartilage regeneration of adipose-derived stem cells in a hybrid scaffold from fibrin-modified PLGA. **Cell Transplantation**, v. 18, p. 159-70, 2009.

WERNER, S.; GROSE, R. Regulation of Wound Healing by Growth Factors and Cytokines. **Physiological Reviews**, v. 83, p. 835–870, 2003.

WU, X.; REN, J.; LI, J. Fibrin glue as the cell-delivery vehicle for mesenchymal stromal cells in regenerative medicine. **Cytotherapy**, v. 14, n. 5, p. 555–562, 1 maio 2012.

YANG, J. et al. Depletion of eosinophil infiltration by anti-IL-5 monoclonal antibody (TRFK-5) accelerates open skin wound epithelial closure. **The American journal of pathology**, v. 151, n. 3, p. 813–819, set. 1997.

YANG, L. et al. Platelet poor plasma gel combined with amnion improves the therapeutic effects of human umbilical cord-derived mesenchymal stem cells on wound healing in rats. **Molecular Medicine Reports**, v. 16, n. 3, p. 3494–3502, 2017.

YOUSUF, Y.; AMINI NIK, S. The Role of Myeloid Lineage Cells on Skin Healing and Skin Regeneration. **Journal of Tissue Science & Engineering**, v. 08, n. 02, p. 1–10, 2017.

YUAN, W.; VARGA, J. Transforming Growth Factor- $\beta$  Repression of Matrix Metalloproteinase-1 in Dermal Fibroblasts Involves Smad3. **Journal of Biological Chemistry**, v. 276, n. 42, p. 38502–38510, out. 2001.

ZEBARDAST, N.; LICKORISH, D.; DAVIES, J. E. Human Umbilical Cord Perivascular Cells (HUCPVCs): A mesenchymal cell source for dermal wound healing. **Organogenesis**, v. 6, n. 4, p. 1–7, 2010.

ZHANG, Q.-Z. et al. Human Gingiva-Derived Mesenchymal Stem Cells Elicit Polarization of M2 Macrophages and Enhance Cutaneous Wound Healing. **Stem Cells.**, v. 28, n. 10, p. 1856–1868, 2010.

ZUK, P. Adipose-Derived Stem Cells in Tissue Regeneration: A Review. **ISRN Stem Cells**, v. 2013, Article ID 713959, p. 35, 2013.