

**UNIVERSIDADE FEDERAL DE VIÇOSA**

**JÚLIA PARISI MARLIÈRE**

**AVALIAÇÃO HEMODINÂMICA E STATUS OXIDATIVO DE ÉGUAS NO  
PERÍODO PRÉ-PARTO**

**VIÇOSA – MINAS GERAIS**

**2024**

**JÚLIA PARISI MARLIÈRE**

**AVALIAÇÃO HEMODINÂMICA E STATUS OXIDATIVO DE ÉGUAS NO  
PERÍODO PRÉ-PARTO**

Dissertação apresentada à Universidade Federal de Viçosa, como parte das exigências do Programa de Pós-Graduação em Medicina Veterinária, para obtenção do título de *Magister Scientiae*

Orientadora: Bruna Waddington de Freitas

Coorientador: Leandro Abreu da Fonseca

**VIÇOSA – MINAS GERAIS**

**2024**

Ficha catalográfica elaborada pela Biblioteca Central da Universidade  
Federal de Viçosa - Campus Viçosa

T

M348a  
2024

Marlière, Júlia Parisi, 1996-

Avaliação hemodinâmica e status oxidativo de éguas no período pré-parto / Júlia Parisi Marlière. – Viçosa, MG, 2024.  
1 dissertação eletrônica (63 f.): il. (algumas color.).

Texto em inglês e português.

Orientador: Bruna Waddington de Freitas.

Dissertação (mestrado) - Universidade Federal de Viçosa, Departamento de Veterinária, 2024.

Inclui bibliografia.

DOI: <https://doi.org/10.47328/ufvbbt.2024.169>

Modo de acesso: World Wide Web.

1. Equinos - Gestação. 2. Doppler, Ultrassonografia.  
3. Estresse oxidativo. I. Freitas, Bruna Waddington de, 1982-.

CDD 22. ed. 636.1082

Bibliotecário(a) responsável: Alice Regina Pinto Pires CRB-6/2523


**JÚLIA PARISI MARLIÈRE**

**AVALIAÇÃO HEMODINÂMICA E STATUS OXIDATIVO DE ÉGUAS NO  
PERÍODO PRÉ-PARTO**

Dissertação apresentada a Universidade Federal de Viçosa, como parte das exigências do Programa de Pós-Graduação em Medicina Veterinária, para obtenção do título de *Magister Scientiae*.


APROVADA: 26 de fevereiro de 2024.

Assentimento:

Documento assinado digitalmente  
 **JULIA PARISI MARLIERE**  
Data: 08/03/2024 16:03:33-0300  
Verifique em <https://validar.iti.gov.br>

---

Júlia Parisi Marlière  
Autora

Documento assinado digitalmente  
 **BRUNA WADDINGTON DE FREITAS**  
Data: 08/03/2024 20:46:30-0300  
Verifique em <https://validar.iti.gov.br>

---

Bruna Waddington de Freitas  
Orientadora

## **AGRADECIMENTOS**

O presente trabalho foi realizado com apoio da Coordenação de Aperfeiçoamento de Pessoal de Nível Superior – Brasil (CAPES) – código de financiamento 001.

Agradeço ao Departamento de Veterinária da Universidade Federal de Viçosa (DVT-UFV), ao Programa de Pós-Graduação em Medicina Veterinária e à Polícia Militar do estado de Minas Gerais, especialmente ao Núcleo de Reprodução Equina (NER) do Regimento de Cavalaria Alferes Tiradentes, pela oportunidade de utilizar sua infraestrutura e animais para a realização do presente trabalho.

Aos professores Bruna Waddington de Freitas e Leandro Abreu da Fonseca, meu agradecimento pela orientação e coorientação durante os últimos dois anos. Aos professores Leandro Licursi de Oliveira e Mariana Machado Neves agradeço por cederem o espaço e infraestrutura do Laboratório de Imunoquímica e Glicobiologia e Laboratório de Biologia Estrutural para a realização das análises que resultaram na produção do presente trabalho. À professora Emily Correna Carlo Reis pelas contribuições que agregaram imensamente à versão final do presente trabalho.

A todos citados, técnicos e colegas, meu agradecimento por dividirem seu tempo, paciência e conhecimento, sem os quais a realização desse trabalho não seria possível.

## RESUMO

MARLIÈRE, Júlia Parisi. Universidade Federal de Viçosa, fevereiro de 2024.  
**Avaliação hemodinâmica e status oxidativo no período pré-parto de éguas.**  
Orientadora: Bruna Waddington de Freitas. Coorientador: Leandro Abreu da Fonseca.

A gestação é uma condição fisiológica delicada e diversos fatores podem colocar em risco a saúde da égua gestante e do feto. Sendo assim, buscou-se avaliar índices ultrassonográficos e marcadores sanguíneos e placentários de estresse oxidativo em éguas com gestações normais e anormais. Nove éguas mestiças da raça Brasileiro de Hipismo foram acompanhadas durante as últimas duas semanas de gestação. Os animais foram alocados em grupos normal ou anormal com base em achados clínicos e ultrassonográficos de anormalidade gestacional. O primeiro estudo comparou índices de pulsatilidade (PI) e resistividade (RI) da artéria uterina ipsilateral ao corno gestante. Valores de PI sofreram queda ( $P < 0,05$ ) entre as semanas dentro do grupo normal, enquanto nenhuma alteração foi encontrada no grupo anormal. Nenhuma diferença significativa ( $P > 0,05$ ) foi encontrada entre os grupos. No segundo estudo, foram realizadas colheitas diárias de sangue a partir de 320 dias de gestação até o dia do parto. As amostras foram centrifugadas e o soro armazenado a  $-20^{\circ}$  C. Três amostras foram obtidas de cada placenta e armazenadas em nitrogênio líquido. Foram realizados os testes de atividade de catalase, atividade de superóxido dismutase, capacidade de redução férrica do plasma, quantificação de proteína carbonilada e determinação de malondialdeído (MDA). Éguas do grupo anormal apresentaram valores maiores ( $P < 0,05$ ) para determinação de MDA nas amostras de sangue na semana que antecedeu os partos. Outros marcadores avaliados não apresentaram resultados significativos ( $P > 0,05$ ). Os estudos produziram dados importantes acerca do status hemodinâmico e oxidativo de éguas durante as duas últimas semanas de gestação.

**Palavras-chave:** Doppler espectral; Estresse oxidativo; Gestação equina

## ABSTRACT

MARLIÈRE, Júlia Parisi. Universidade Federal de Viçosa, February, 2024. **Hemodynamic evaluation and oxidative status in mares in the prepartum period.** Adviser: Bruna Waddington de Freitas. Co-adviser: Leandro Abreu da Fonseca.

Pregnancy is a delicate physiological condition, and various factors can pose a risk to the health of the pregnant mare and the fetus. This study aimed to assess ultrasonography indices and blood and placental markers of oxidative stress in mares with normal and abnormal pregnancies. Nine Brazilian Sport Horses crossbred mares were monitored during the last two weeks of gestation. They were divided into normal or abnormal groups based on clinical and ultrasonographic findings indicative of gestational abnormalities. The first study aimed to compare pulsatility (PI) and resistivity (RI) indices of the uterine artery ipsilateral to the fetus. PI values showed a decrease ( $P < 0.05$ ) between weeks within the normal group, while no changes were found within the abnormal group. No differences were found between the groups. In the second study, the mares underwent daily blood sample collection from day 320 of gestation until delivery. The samples were centrifuged and stored at  $-20^{\circ}\text{C}$ . Three samples were obtained from each placenta and stored in liquid nitrogen. Five tests were performed on all samples: catalase activity, superoxide dismutase activity, ferric reducing ability of plasma, quantification of carbonylated protein, and malondialdehyde (MDA) determination. Mares in the abnormal group showed higher values ( $P < 0.05$ ) for MDA determination in blood samples. Other markers of oxidative stress did not show differences among or between groups. Our studies provided important data regarding the hemodynamic and oxidative status of mares during the last two weeks of pregnancy.

**Keywords:** Equine pregnancy; Oxidative stress; Spectral Doppler

## SUMÁRIO

1.1. Introdução .....	9
1.2. Gestações de alto risco.....	9
1.3. Placentite .....	10
1.4. Ultrassonografia Doppler .....	13
1.5. Estresse oxidativo .....	15
1.5.1. Processos inflamatórios e infecciosos .....	18
1.6. Referências Bibliográficas.....	19
1. 2. CAPÍTULO 2.....	26
Abstract.....	27
2.1. Introduction .....	28
2.2. Materials and methods.....	29
2.2.1. Animals and location.....	29
2.2.2. Combined thickness of the uterus and placenta evaluation .....	29
2.2.3. Spectral-Doppler evaluation.....	29
2.2.4. Group design .....	30
2.2.5. Statistical analysis .....	30
2.3. Results.....	30
2.3.1. Experimental groups.....	30
2.3.2. Gestational length and combined thickness of uterus and placenta ....	31
2.3.3. PI and RI indices.....	32
2.3.4. Fetal membranes expulsion.....	32
2.4. Discussion.....	34
2.5. Conclusion .....	36
2.6. References.....	36
2. 3. CAPÍTULO 3.....	43
Abstract.....	44
3.1. Introduction .....	45
3.2. Materials and methods.....	46
3.2.1. Animals and location.....	46
3.2.2. Ultrasonographic examination .....	46
3.2.3. Experimental groups.....	47
3.2.4. Blood samples .....	47

3.2.5. Fetal membranes expulsion and placenta samples .....	47
3.2.6. Oxidative stress markers and enzymatic activity .....	48
3.2.7. Statistical Analysis .....	48
3.3. Results .....	49
3.3.1. Experimental groups .....	49
3.3.2. Gestational length and CTUP measurements.....	49
3.3.3. Fetal membranes expulsion.....	50
3.3.4. Blood oxidative stress markers and enzymatic activity .....	52
3.3.5. Placenta oxidative stress markers and enzymatic activity .....	54
3.4. Discussion.....	56
3.5. Conclusion .....	57
3.6. References.....	57

## 1. CAPÍTULO 1

Revisão bibliográfica

## **1.1. Introdução**

Segundo dados do Instituto Brasileiro de Geografia e Estatística, em 2022, o rebanho brasileiro de equinos era composto por 5.834.544 animais, sendo o estado de Minas Gerais o maior produtor (IBGE, 2022). No ano de 2016, o valor movimentado pelo setor ultrapassou R\$ 16 bilhões, com mais de 3 milhões de pessoas ocupando postos de trabalho (MAPA, 2016).

Levando em consideração a importância da equideocultura na economia brasileira, complicações gestacionais em éguas, como distocias e morte perinatal geram um impacto negativo importante sobre a rentabilidade de criadores de equinos. Abortamentos e fetos natimortos estão entre os maiores contribuintes para a mortalidade em equinos e representam uma grande perda para a equideocultura. Para o criador, as perdas gestacionais resultam na quebra de expectativas, perda de investimentos e desperdício de potencial genético (Juffo et al., 2022). Por isso, o desenvolvimento de métodos de avaliação das condições placentárias e fetais ao longo da gestação se mostra essencial ao sucesso na criação de cavalos, possibilitando o diagnóstico de enfermidades gestacionais e avaliação contínua da evolução e prognóstico da fêmea doente.

A ultrassonografia é uma ferramenta essencial ao monitoramento do bem-estar fetal e diagnóstico de diversas condições patológicas, sendo de fácil utilização e relativo baixo custo. A associação entre a espessura da junção uteroplacentária (JUP) e avaliação da ecogenicidade dos líquidos fetais são capazes de fornecer informações necessárias ao diagnóstico das principais anormalidades gestacionais (Freitas e Marlière, 2023).

Entretanto, diversas questões relativas à fisiologia da gestação na espécie equina ainda precisam de esclarecimento, em especial quanto às modificações bioquímicas e hemodinâmicas da fêmea gestante. Tais alterações representam um importante potencial no estabelecimento de possíveis novos biomarcadores da saúde placentária e gestacional.

## **1.2. Gestações de alto risco**

A gestação é uma condição fisiológica dinâmica e diversas condições podem colocar em risco a saúde da égua gestante e, em consequência, do feto. As maiores

causas de perdas gestacionais no último trimestre incluem agentes microbiológicos, gestações gemelares, anormalidades placentárias e/ou fetais, anormalidades estruturais (como hidropsia fetal, ruptura do tendão pré-púbico e presença de hérnias), além de doenças sistêmicas (Juffo et al., 2022).

Gestações de alto risco podem ser categorizadas de acordo com sua origem: materna, fetal ou placentária. Apesar dessas categorias não serem absolutas, analisá-las sob essa perspectiva permite a observação das tendências de diagnóstico e prognóstico (Masko et al., 2020). Quadros de hipóxia, infecção e falhas no desenvolvimento intrauterino são os responsáveis pelos maiores riscos à sobrevivência neonatal. Cada uma dessas complicações, isoladas ou em associação, podem resultar em partos prematuros, morte fetal e anormalidades comportamentais ou do desenvolvimento neonatal (Abraham e Bauquier, 2021).

O feto equino é dependente dos níveis de glicose e oxigênio disponíveis na circulação materna para seu desenvolvimento. Episódios de hipóxia ou desnutrição materna, mesmo que temporária, são capazes de alterar o metabolismo e função endócrina fetais. Quando o aporte de nutrientes e energia se torna limitado, há restrição do crescimento fetal intrauterino. Alterações no crescimento e desenvolvimento fetais também são observados quando há insuficiência placentária ou redução do aporte sanguíneo uterino ou do cordão umbilical (Peugnet et al., 2013).

Independentemente da causa, a identificação precoce da égua em risco permite que o médico veterinário mantenha a fêmea sob supervisão constante dos parâmetros maternos e fetais e realize a intervenção mais adequada precocemente, aumentando as chances de sucesso da gestação (Masko et al., 2020).

### **1.3. Placentite**

A placentação na espécie equina exige a interdigitação entre os tecidos maternos e fetais ao longo de toda superfície endometrial de maneira a permitir o máximo desenvolvimento fetal durante a vida intrauterina. Portanto, quaisquer condições capazes de afetar a eficiência das trocas entre mãe e feto representam um risco ao bem-estar e sobrevivência fetais.

A placentite é considerada uma das mais importantes causas de perda gestacional observada em éguas. Entretanto, em um trabalho conduzido por Maclealy et al. (2022), mostrou que apenas 16% dos casos de perda gestacional analisados entre os anos de 1960 e 2020 foram associados à quadros de placentite. Muitos casos de placentite não recebem os diagnósticos histopatológico e microbiológico *post mortem* e, portanto, não são contabilizados. Portanto, acredita-se ainda que a placentite seja um dos principais responsáveis pela ocorrência de perdas durante a gestação.

A disfunção resultante das placentites pode levar não apenas ao abortamento ou a fetos natimortos, mas também ao nascimento de potros prematuros, fracos ou sépticos, que necessitam de cuidado intensivo imediatamente após o parto (Toribio, 2019; Scalco e Curcio, 2021). Localização geográfica, características populacionais e o emprego de biotécnicas reprodutivas podem dificultar a identificação e caracterização das alterações placentárias causadas por cada patógeno (Hong et al., 1993).

Infecções bacterianas são mais comuns quando comparadas àquelas de origem fúngica (Orellana-Guerrero et al., 2019), mas contaminações mistas podem ocorrer. Apesar da interferência da localização geográfica sobre o perfil de microrganismos mais isolados, *Streptococcus equi* subesp. *zoopidemicus*, *Escherichia coli*, *Streptococcus* beta-hemolítico, *Leptospira* spp, *Pseudomonas aeruginosa*, *Pasteurella pneumotropica* e *Klebsiella pneumoniae* são descritos com alta frequência. Dentre os fungos, os mais comumente isolados são *Aspergillus* spp, *Candida albicans* e *Mucor* spp. Infecções virais podem ocorrer, mas representam uma pequena parcela, sendo os Herpesvírus tipo-1 (EHV-1) e tipo-4 (EHV-4) e o vírus da arterite equina (EVA) os mais encontrados (Laugier et al., 2011; Marcolongo-Pereira et al., 2012; Juffo et al., 2022).

A forma mais comum de contaminação da placenta ocorre quando bactérias migram por via ascendente através do canal vaginal e ultrapassam a barreira cervical, alcançando o ambiente uterino tipicamente no terço final de gestação (LeBlanc et al., 2012). Grande parte das fêmeas acometidas é multípara e apresenta falhas anatômicas da porção caudal do aparelho urogenital, como defeitos na conformação vulvar, incompetência da prega vestíbulo-vaginal, lacerações e fibroses cervicais (Crabtree, 2023).

Em modelos experimentais para indução de placentites ascendentes, o tampão mucoso cervical é retirado, parcial ou completamente, para permitir a inoculação do microrganismo de interesse. Portanto, acredita-se que a falha na proteção do ambiente uterino pelo tampão cervical seja também um importante fator em placentites que ocorrem de maneira espontânea (McGothlin et al., 2004).

A chegada do patógeno no útero leva a uma resposta do organismo com intensa infiltração de células imunes e liberação de citocinas pró-inflamatórias (El-Sheikh Ali et al., 2021). O aumento na expressão de interleucinas (IL) como as IL-6 e IL-8 na estroma cervical e corioalantoide, além de IL-1 em outros tecidos placentários leva ao aumento na produção e secreção de prostaglandinas, como a PGE<sub>2</sub> e PGF<sub>2α</sub>. As prostaglandinas são essenciais a diversas etapas do parto, como dilatação cervical, ruptura do corioalantoide e estímulo à contração da camada muscular uterina justificando a ocorrência de abortamentos e partos prematuros (Lyle, 2014). Essa ideia é corroborada pelo padrão de ativação gênica alterado observado em éguas com placentite ascendente induzida de forma experimental, resultando em uma grande expressão de sinalizadores inflamatórios e ativação de receptores, principalmente *Toll-like receptors* (TLRs), alterando o padrão de ativação miometrial nessas fêmeas (El-Sheikh Ali et al., 2020).

O diagnóstico é baseado na coleção do histórico reprodutivo da fêmea, exame físico e ultrassonográfico. O sinal clínico mais comum entre os animais doentes é o desenvolvimento precoce do úbere, com ou sem presença de galactorreia. O desenvolvimento da glândula mamária, em gestações normais, ocorre por volta de 3 a 6 semanas antes do parto, com crescimento ainda mais acelerado 2 a 1 semana antes da data prevista. Entretanto, o desenvolvimento mamário precoce não é sinal patognomônico de placentite, mas um sinal inespecífico de aborto iminente, podendo indicar outros distúrbios como gestações gemelares, anormalidades placentárias e torções de cordão umbilical. Na maior parte dos casos, o desenvolvimento precoce da glândula mamária só acontece quando o quadro de placentite é avançado, muitas vezes já com sinais de separação placentária (Crabtree, 2023).

A presença de secreção vulvar não pode ser considerada um sinal consistente da placentite bacteriana. Em muitos casos, o volume de secreção é pequeno e pode passar despercebido ou, ainda, ser removido pelo constante movimento da cauda do animal (MacPherson e Bailey, 2008). A infecção leva ao espessamento e, em

muitos casos, ulceração do corioalantoide, com alteração do aspecto da estrela cervical. Como a principal rota de infecção é ascendente, os primeiros sinais de anormalidade placentária ocorrem na estrela cervical (Giles et al., 1993). O exame ultrassonográfico transretal é superior, quando comparado a avaliação transabdominal, na avaliação da junção uteroplacentária (JUP) a partir da segunda metade da gestação (Crabtree, 2023).

A avaliação da espessura da JUP é feita no corpo uterino, cranioventralmente à estrela cervical. Após a identificação da artéria uterina, a JUP se apresenta como uma banda hiperecoica, de aspecto homogêneo. Três medições são feitas e a média obtida pode ser comparada a valores de referência descritos na literatura (Renaudin et al., 1997; Troedsson et al., 1997). Valores acima do intervalo de normalidade são associados a quadros de placentite ascendente (Requena et al., 2017; Kimura et al., 2018).

O exame ultrassonográfico também pode ser utilizado para avaliar a ecogenicidade dos líquidos amniótico e alantoideano. Esses permanecem anecoicos durante a maior parte da gestação; a partir do terço final, debris celulares e proteináceos começam a se acumular. As partículas podem ser observadas em ambos os fluidos a partir do 4º mês de gestação (Adams-Brendemuehl e Pipers, 1987; Reef et al., 1995). A ecogenicidade pode ser graduada de I a IV (Renaudin et al., 1999). Conteúdos de alta ecogenicidade, associados, ou não, ao espessamento da JUP são indicativos de placentite (Reef, 1998).

#### **1.4. Ultrassonografia Doppler**

A ultrassonografia é uma das mais importantes e mais utilizadas ferramentas de avaliação do organismo de maneira não invasiva. Entre as diversas técnicas ultrassonográficas que podem ser empregadas na rotina clínica, a utilização do modo Doppler possibilita a aferição de índices hemodinâmicos em tempo real, oferecendo indicadores úteis no diagnóstico de diversas enfermidades (Carvalho et al., 2008).

A ultrassonografia Doppler possui diversas vantagens sobre o método tradicional de avaliação da anatomia e funcionalidade do sistema vascular, a angiografia. Além do menor grau de invasividade e menor tempo de realização do

exame, a técnica não apresenta contraindicação para pacientes com alergias a contrastes intravenosos ou doença renal (Gao et al., 2010).

A técnica em modo Doppler é empregada de maneira rotineira na medicina humana, durante o exame obstétrico, devido aos mínimos efeitos e baixo custo de realização. A detecção de alterações como hipertensão arterial materna (Gyselaers et al., 2019), restrição do crescimento intrauterino em gestações gemelares (Bennasar et al., 2017) e determinação de prognóstico gestacional (Habberman et al., 2004) são possíveis através do emprego do modo Doppler e parâmetros de normalidade para essas avaliações estão disponíveis na literatura.

Entretanto, esse ainda é um exame pouco utilizado na prática médica veterinária. Alguns dos limitantes para sua utilização em larga escala estão o custo do equipamento e falta de treinamento técnico, necessidade de colaboração do paciente examinado, que precisa ser mantido imóvel durante a realização do exame. Entretanto, o maior limitante para o emprego da técnica Doppler ainda é a inexistência de valores de referência para serem utilizados como parâmetro durante o exame ultrassonográfico.

Na reprodução animal, a técnica já foi empregada para a avaliação da gestação em ovelhas (Beltrame et al.; Elmetwally e Bollwein, 2017), seleção de receptoras equinas em sistemas de transferência de embrião (Ferreira et al., 2020), avaliação da vascularização de corpos lúteos em vacas (Pugliesi et al., 2023) e avaliação do desenvolvimento placentário em éguas da raça Mangalarga Marchador (Campos et al., 2022).

Dentre as modalidades de avaliação ultrassonográfica pelo método Doppler, o modo espectral (ou pulsado) permite a avaliação dinâmica do fluxo sanguíneo a partir do eco refletido pelos componentes celulares do sangue e das ondas espectrais formadas a partir dos mesmos (Nelson e Pretorius, 1988).

O modo espectral examina de maneira quantitativa o fluxo sanguíneo dentro de um vaso. As alterações nas frequências refletidas são traduzidas em gráficos de ondas, cada uma representando um ciclo cardíaco completo. A partir desse exame é possível a determinação dos índices de pulsatilidade (PI) e resistividade (RI), além de valores de velocidade máxima média e velocidades no pico sistólico e final da diástole (Ginther, 2007).

Durante a avaliação Doppler, a obtenção de valores fidedignos para os índices velocimétricos é diretamente afetada pelo ângulo de insonação entre o transdutor

e o vaso a ser avaliado, que não deve superar 60°. Para a avaliação de vasos profundos e tortuosos, o uso dos valores PI e RI são mais indicados para a avaliação hemodinâmica, já que esses não dependem de um ângulo de insonação específico (Ginther, 2007).

Na obstetrícia veterinária, alguns trabalhos já exploraram a identificação de padrões hemodinâmicos em cadelas gestantes para o estabelecimento de valores de normalidade durante o período final de gestação e identificação da proximidade do parto através da avaliação da artéria umbilical (Giannico et al., 2015; 2016).

### **1.5. Estresse oxidativo**

O equilíbrio redox em células, tecidos ou líquidos biológicos é estabelecido pelos pares redox que trocam elétrons constantemente, alternando entre os estados oxidado e reduzido (Vasconcelos et al., 2007). A formação de espécies reativas ocorre de maneira fisiológica e contínua no organismo, como resultado dos processos metabólicos.

O conceito de radical livre engloba qualquer molécula capaz de existir de maneira independente que contém um ou mais elétrons desemparelhados. Já o termo “espécie reativa”, mais abrangente, inclui todas as espécies de radicais livres e, ainda, inclui aquelas que, apesar de não apresentarem elétrons desemparelhados, possuem alta reatividade decorrente de sua instabilidade. Por esse motivo, a definição de espécie reativa vem substituindo o conceito anterior (Nakai e Tsuruta, 2021).

O termo espécie reativa de oxigênio (ERO) inclui radicais superóxido ( $O_2^{\cdot-}$ ), hidroxila (OH), peróxido de hidrogênio ( $H_2O_2$ ), radicais peroxila ( $ROO^{\cdot}$ ), alcóxido ( $RO^{\cdot}$ ), hidroperóxidos de lipídios ( $LOOH^{\cdot}$ ), peroxinitrito ( $ONOO^-$ ), ozônio ( $O_3$ ) e oxigênio singleto ( $^1O_2$ ), entre outros. O óxido nítrico (NO) e dióxido de nitrogênio ( $NO_2$ ), além do peroxinitrito, compõem o grupo das espécies reativas de nitrogênio (ERN), produzidas através da reação entre o óxido nítrico e o radical superóxido ou peróxido de hidrogênio. Existem ainda espécies que contém cloro, como o ácido hipocloroso (HOCl), chamadas espécies reativas de cloro (ERC) e espécies reativas de bromo (ERB), com o ácido hipobromoso (HOBr) como exemplo, menos

exploradas na literatura. Em muitos casos, essas classificações podem se sobrepor (Nakai e Tsuruta, 2021).

Esses radicais participam como mediadores para a transferência de elétrons em diversas reações bioquímicas normais, possibilitando a produção de energia, ativação de mecanismos de defesa celular durante processos infecciosos, regulação do crescimento celular, senescência e apoptose, por exemplo. Todos os organismos aeróbicos estão continuamente sujeitos aos efeitos oxidantes desses metabólitos, uma vez que todas essas espécies são fruto do metabolismo aeróbico (Zhang et al., 2016).

Em organismos saudáveis, a produção de espécies reativas, na maior parte do tempo, é balanceada pela ação dos sistemas antioxidantes. Em condições normais, os organismos aeróbicos são capazes de metabolizar até 90% do oxigênio consumido pelas mitocôndrias por meio de redução tetravalente, intermediadas pelo sistema enzimático citocromo, em um processo denominado fosforilação oxidativa (Zhang et al., 2016).

O restante do oxigênio consumido é utilizado pelos sistemas enzimáticos (oxidases, oxigenases e citocromo P450) ou por reações de oxidação direta. Porém, quando produzidos em excesso, podem acarretar danos oxidativos às células, afetando seu funcionamento e o equilíbrio homeostático (Halliwell, 1992).

De acordo com Halliwell e Gutteridge (2007) o dano oxidativo pode ser definido como “o dano biomolecular ocasionado pelo ataque de espécies reativas sobre os constituintes de um organismo vivo”. O dano causado a biomoléculas é resultado do grave desbalanço entre a formação e neutralização das espécies reativas, chamado estresse oxidativo. A concentração das espécies reativas pode se elevar por meio da interação celular com agentes exógenos, como radiação ionizante, luz ultravioleta, xenobióticos, poluentes ambientais e invasão por microrganismos patogênicos e produção de toxinas, mas também por agentes endógenos, como quadros de hipóxia e isquemia, hiperglicemia e hiperlipidemia (Pizzino et al., 2017).

O acúmulo de espécies reativas leva à oxidação de biomoléculas, como peroxidação de membranas lipídicas, dano proteico, oxidação de carboidratos, destruição do DNA nuclear e mitocondrial e RNA. As consequências do estresse oxidativo incluem proliferação, adaptação, senescência e morte celular, podendo ocorrer de forma isolada ou em combinação (Pizzino et al., 2017).

Os efeitos deletérios do oxigênio dependem de diversos fatores, como idade, estado fisiológico e dieta. Quando analisamos um único indivíduo, tecidos e tipos celulares distintos também podem ser afetados diferentemente. A qualidade da dieta e, conseqüentemente, as concentrações de vitamina A, C e E, micronutrientes e ácidos graxos polinsaturados também alteram a resposta individual ao estresse oxidativo. A extensão dessas conseqüências depende diretamente da gravidade do insulto e do tipo celular atingido (Pizzino et al., 2017).

A resposta celular ao estresse oxidativo é complexa e conseqüências positivas e negativas são possíveis. O estímulo à proliferação celular permite a cicatrização de feridas, ao mesmo tempo que pode gerar fibrose; o aumento nas defesas celulares (como chaperonas e aumento na expressão de enzimas antioxidantes) pode tornar um tecido mais resistente a desafios e danos celulares futuros, mas também pode gerar a permanência de células anormais; a apoptose e senescência eliminam, ou pelo menos impedem a divisão, de células que sofreram danos excessivos ao seu material genético, mas células saudáveis e essenciais podem ser eliminadas nesse processo (Halliwell e Gutteridge, 2007).

Com o objetivo de eliminar ou modificar a estrutura das EROs e mitigar seus efeitos nocivos sobre os tecidos, o organismo conta com sistemas antioxidantes que atuam sob diferentes mecanismos. Moléculas com capacidade antioxidante podem ser sintetizadas pelo próprio organismo ou podem ser obtidas através da dieta (Sies, 1991). Segundo Halliwell (1992), substâncias antioxidantes podem ser definidas como aquelas que, quando presentes em baixas concentrações quando comparadas a um substrato passível de oxidação, previnem ou retardam significativamente a oxidação desse substrato.

As defesas antioxidantes do organismo incluem sistemas enzimático e não-enzimático. Esse inclui vitaminas lipossolúveis, como o grupo dos  $\alpha$ -tocoferóis (vitamina E) e  $\beta$ -caroteno (precursor da vitamina A), vitaminas hidrossolúveis, como o ácido ascórbico (vitamina C) e vitaminas do complexo B, oligoelementos (como zinco, selênio, cobre, magnésio, ferro e manganês), ubiquinona, celuroplasma, taurina e outros componentes fenólicos (Halliwell, 1992).

O sistema enzimático inclui agentes que ativamente removem espécies reativas e tem entre seus principais agentes a superóxido dismutase (SOD), glutathione peroxidases (GPx), mieloperoxidases (MPO), óxido nítrico sintase (NOS) e catalase (CAT). Apesar da separação entre componentes enzimáticos e não-

enzimáticos, os antioxidantes trabalham em conjunto, com minerais e vitaminas desempenhando o papel de coadjuvantes ou catalíticos da atividade enzimática (Halliwell, 1992)

Os mecanismos de defesa antioxidante mantêm a baixa concentração de espécies reativas, mas não os elimina completamente, pois a manutenção do sistema antioxidante em alto nível de funcionamento representa um elevado custo energético para o organismo. Assim, a reparação, ou até mesmo a substituição, de biomoléculas lesadas pela ação das espécies reativas se torna mais vantajosa. Em alguns casos, os mecanismos antioxidantes são incapazes de interceptar e neutralizar a ação das espécies reativas (Halliwell, 1992).

#### 1.5.1. Processos inflamatórios e infecciosos

A formação de espécies reativas é essencial ao funcionamento do sistema imune inato. Agentes oxidantes, tanto quanto antioxidantes, participam ativamente nas vias pelas quais o organismo busca retornar à homeostase, como mudanças hemodinâmicas e alteração da permeabilidade vascular, por exemplo (Vajdovich, 2011). O desequilíbrio entre as concentrações de espécies reativas e atividade dos sistemas antioxidantes é essencial à regulação da expressão gênica em situações fisiológicas e patológicas. Nesse cenário, os agentes oxidantes assumem o papel de sinalizadores para engatilhar e perpetuar processos inflamatórios (Mandelker, 2011).

Durante a fagocitose de microrganismos patogênicos, o consumo de oxigênio pelos fagócitos se eleva rapidamente, fenômeno conhecido como explosão respiratória, descrita por Baldrige e Gerard (1933). Esse evento é resultado da ativação de um complexo enzimático presente na membrana plasmática dos fagócitos, responsável pela formação de vacúolos fagocíticos. Como resultado dessa ativação enzimática, uma molécula de NADPH sofre oxidação, liberando dois elétrons que serão utilizados na reação de redução de duas moléculas de oxigênio, formando dois radicais superóxido (Babior, 2004). Nesse momento, o consumo de oxigênio de neutrófilos, macrófagos, monócitos e eosinófilos é de 10 a 20 maior do que seu consumo em “repouso” (Li et al., 2021).

Diversos microrganismos são eliminados pela ação do peróxido de hidrogênio, produzido pela dismutação de radicais superóxido. O  $H_2O_2$ ,

diferentemente do radical  $O_2^{\cdot-}$ , é capaz de atravessar membranas celulares e a parede bacteriana, exercendo seus efeitos tóxicos diretamente sobre constituintes celulares ou indiretamente, pela produção de radicais hidroxila. Após a formação do vacúolo fagocítico, a enzima mieloperoxidase é ativada. A MPO, representando entre 2 a 5% das proteínas neutrofílicas totais, possui baixa especificidade e, por isso, é capaz de oxidar uma grande variedade de substratos. Acredita-se que o mecanismo de ação da MPO seja a partir da oxidação de íons cloreto ( $Cl^-$ ) e produção de ácido hipocloroso, altamente reativo e capaz de danificar proteínas de membrana, proteínas produtoras de ATP e material genético bacteriano, viral e fúngico (Li et al., 2021).

## 1.6. Referências Bibliográficas

ABRAHAM, M.; BAUQUIER, J.; Causes of equine perinatal mortality. **The Veterinary Journal**, v.273, 105675, 2021.

ADAMS-BRENDEMUEHL, C.; PIPERS, F.S. Antepartum evaluations of equine fetus. **Journal of Reproduction & Fertility, Suppl.** 35, p.565-573, 1987.

BABIOR, B.M. Phagocytes and Oxidative Stress. **American Journal of Medicine**, v.109, n.1, p.33-44, 2004.

BALDRIDGE, C.; GERARD, R. The extra respiration of phagocytosis. **American Journal of Physiology**, v.103, n.1, p.235-236, 1933.

BELTRAME, R. T.; COVRE, C.; LITTIG, L. B.; MARTINS, A. B.; QUIRINO, C. R.; BARTHOLAZZI JUNIOR, A.; DA COSTA, R. L. D. Transrectal Doppler sonography of uterine blood flow in ewes during pregnancy. **Theriogenology**, v.91, p.55-61, 2017.

BENNASAR, M.; EIXARCH, E.; MARTINEZ, J. M.; GRATACÓS, E. Selective intrauterine growth restriction in monochorionic diamniotic twin pregnancies. **Seminars in Fetal & Neonatal Medicine**, v.22, n.6, p.376-382, 2017.

CAMPOS, I. S.; DE SOUZA, G. N.; GOMES, G. M.; PINNA, A. E.; FERREIRA, A. M. R. Spectral Doppler ultrasound in the placental development of Mangalarga Marchador mares. **Theriogenology**, v.180, p.171-175, 2022.

CARVALHO, C. F.; CHAMMAS, M. C.; CERRI, G. G. Morfologia duplex Doppler dos principais vasos sanguíneos abdominais em pequenos animais: revisão bibliográfica. **Ciência Rural**, v.38, n.3, p.880-888, 2008.

ELMETWALLY, M.; BOLLWEIN, H. Uterine blood flow in sheep and goats during the peri-parturient period assessed by transrectal Doppler sonography. **Animal Reproduction Science**, v.176, p.32-39, 2017).

EL-SHEIKH ALI, H.; BOAKARI, Y.L.; LOUX, S.C.; DINI, P.; SCOGGIN, K.E.; ESTELLER-VICO, A.; KALBFLEISCH, T.; BALL, B.A. Transcriptomic analysis reveals the key regulators and molecular mechanisms underlying myometrial activation during equine placentitis. **Biology of Reproduction**, v.102, n.6, p.1306-1325, 2020.

FERREIRA, B.W.; MARLIÈRE, J.P. Manejo das principais anormalidades gestacionais em éguas. **Revista Brasileira de Reprodução Animal**, v.47, n.2, p.205-211, 2023.

FERREIRA, C.S.C.; MORAIS, R.C.L.; DE ANDRADE, A.B.P.; BALARO, M.F.A.; RIBAS, J.A.S.; GOMES, G.M.; PINNA, A.E. Spectral Doppler ultrasound in selecting an equine embryo receiver. **Reproduction in domestic animals**, v.55, n.6, p.747-752, 2020.

GAO, J.; SHIH, G.; AUH, Y. H.; PRINCE, M. R.; FUNDERBURK, J.; NG, A. Pitfalls and sources of error of color duplex sonography in screening for renovascular hypertension. **International Journal of Nephrology & Urology**, v.2, n.1, p.212-223, 2010.

GILES, R.C.; DONAHUE, J.M.; HONG, C.B.; TUTTLE, P.A.; PETRITES-MURPHT, M.B.; POONACHA, K.B.; ROBERTS, A.W.; TRAMONTIN, R.R.; SMITH, B.;

SWERCZEK, T.W. Causes of abortion, stillbirth and perinatal death in horses: 3.527 cases (1986-1991). **Journal of American Veterinary Medical Association**, v.203, n.8, p.1170-1175, 1993.

GINTHER, O.J. **Ultrasonic imaging and animal reproduction: Color-Doppler ultrasonography**. Madison: Equiservices Publishing, 2007.

GYSELAERS, W.; VONCK, S.; STAELENS, A. S.; LANSSENS, D.; TOMSIN, K.; OBEN, J.; DREESEN, P.; BRUCKERS, L. Gestational hypertensive disorders show unique patterns of circulatory deterioration with ongoing pregnancy. **American Journal of Physiology. Regulatory, Integrative and Comparative Physiology**, v.316, n.3, p.210-221, 2019.

HABBERMAN, S.; BRACERO, L. A.; BRYNE, D. W. Spectral Doppler index mapping of the umbilicoplacental circulation and pregnancy outcome. **Gynecologic and Obstetric Investigation**, v.58, n.1, p.1-7, 2004.

HALLIWELL, B. Reactive oxygen species and the central nervous system. **Journal of Neurochemistry**, v.59, n.1, p.609-623, 1992.

HALLIWELL, B.; GUTTERIDGE, J.M.C. **Free Radicals in Biology and Medicine**. 4th edition. New York: Oxford University Press, 2007. 851p.

HONG, C.B.; DONAHUE, J.M.; GILES JR., R.C.; PETRITES-MURPHY, M.B.; POONACHA, K.B.; ROBERTS, A.W.; SMITH, B.J.; TRAMONTIN, R.R.; TUTTLE, P.A.; SWERCZEK, T.W. Etiology and pathology of equine placentitis. **Journal of Veterinary Diagnostic Investigation**, v.5, n.1, p.56-63, 1993.

Instituto Brasileiro de Geografia e Estatística. Rebanho de Equinos (Cavalos). <https://www.ibge.gov.br/explica/producao-agropecuaria/equinos/br>. Acessado em 15 de dezembro de 2023.

JUFFO, G.D.; ANTONIASSI, N.A.B.; BASSUINO, D.M.; GOMES, D.C.; SNEL, G.G.M.; PAVARINI, S.P.; DRIEMEIER, D. Abortion, stillbirth and perinatal mortality in horses. **Pesquisa Veterinária Brasileira**, v.42, 06808, 2022.

KIMURA, Y.; HANEDA, S.; AOKI, T.; FURUOKA, H.; MIKI, W.; FUKUMOTO, N.; MATSUI M.; NAMBO, Y. Combined thickness of the uterus and placenta and ultrasonographic examinations of uteroplacental tissues in normal pregnancy, placentitis, and abnormal parturitions in heavy draft horses. **Journal of Equine Science**, v.29, n.1, p.1-8, 2018.

LAUGIER, C.; FOUCHER, N.; SEVIN, C.; LEON, A.; TAPPREST, J. A 24-year retrospective study of equine abortion in Normandy (France). **Journal of Equine Veterinary Science**, v.31, n.3, p.116-123, 2011.

LI, H.; ZHOU, X.; HUANG, Y.; LIAO, B.; CHENG, L.; REN, B.; Reactive Oxygen Species in Pathogen Clearance: The Killing Mechanisms, the Adaptation Response, and the Side Effects. **Frontiers in Microbiology**, v.11, 622534, 2021.

MACPHERSON, M.L.; BAILEY, C.S. A clinical approach to managing the mare with placentitis. **Theriogenology**, v.70, n.3, p.435-440, 2008.

MANDELKER, L. Oxidative Stress, Free Radicals, and Cellular Damage. In: MANDELKER, L. VAJDOVICH, P. **Oxidative Stress in Applied Basic Research and Clinical Practice: Studies on Veterinary Medicine**. 2011<sup>th</sup> edition. Humana Press, New York, 2011. p.1-18.

MARCOLONGO-PEREIRA, C.; ADRIEN, M.L.; LADEIRA, S.R.L.; SOARES, M.P.; ASSIS-BRASIL, N.D.; SCHILD, A.L. Abortos em equinos na região Sul do Rio Grande do Sul: estudo de 72 casos. **Revista Brasileira de Ciência Veterinária**, v.32, n.1, p.22-26, 2012.

MASKO, M.; DOMINO, M.; SKIERBISZEWSKA, K.; ZDROJKOWSKI, L.; JASINKI, T.; GAJEWSKI, Z. Monitoring of the mare during the perinatal period at the clinic and in the stable. **Equine Veterinary Education**, v.32, n.12, p.654-663, 2020.

MACLEAY, C. M.; CARRICK, J.; SHEARER, P.; BEGG, A.; STEWART, M.; HELLER, J.; CHICKEN, C.; BROOKES, V. J. A Scoping Review of the Global Distribution of Causes and Syndromes Associated with Mid to Late Term Pregnancy Loss in Horses Between 1960 and 2020. **Veterinary Science**, v.9, n.4, p.186-202, 2022.

MCGOTHLIN, J.A.; LESTER, G.D.; HANSEN, P.J.; THOMAS, M.; PABLO, L.; HAWKINS, D.L.; LEBLANC, M.M. Alteration in uterine contractility in mares with experimentally induced placentitis. **Reproduction**, v.127, n.1, p.57-66, 2004.

Ministério da Agricultura, Pecuária e Abastecimento. Revisão do Estudo do Complexo do Agronegócio do Cavalo. Brasília, 2016.

MORRIS, S. KELLEMAN, A.A.; STAWICKI, R.J.; HANSEN, P.J.; SHEERIN, P.C.; PACCAMONTI, D.L. LEBLANC, M.M. Transrectal ultrasonography and plasma progesterin profiles identifies feto-placental compromise in mares with experimentally induced placentitis. **Theriogenology**, v.67, n.4, p.681-689, 2007.

NAKAI, K.; TSURUTA, D. What are Reactive Oxygen Species, Free Radicals, and Oxidative Stress in Skin Disease?. **International Journal of Molecular Sciences**, v.22, 107999, 2021.

NELSON, T.R.; PRETORIUS, D.H. The Doppler Signal: Where Does It Come From and What Does It Mean?. **American Journal of Roentgenology**, v.151, n.3, p.439-447, 1988.

ORELLANA-GUERRERO, D.; RENAUDIN, C.; EDWARDS, L.; ROSE, E.; ALEMAN, M.; MOORE, P.F.; DUJOVNE, G. Fungal placentitis caused by *Aspergillus terreus* in a mare: case report. **Journal of Equine Veterinary Science**, v.83, 102799, 2019.

PEUGNET, P. M.; VALENTINO, S.; TARRADE, A.; WIMEL, L.; REIGNER, F.; SERTEYN, D. D. A.; CHAVETTE-PALMER, P. Intrauterine growth restriction is associated with strong alterations in placental structure and function in horses. **Reproduction, Fertility and Development**, v.26, n.1, p.150-151, 2013.

PIZZINO, G.; IRRERA, N.; CUCINOTTA, M.; PALLIO, G.; MANNINO, F.; ARCORACI, V.; SQUADRITO, F.; ALTAVILLA, D.; BITTO, A. Oxidative Stress: Harms and Benefits for Human Health. **Oxidative Medicine and Cellular Longevity**, 8416763, 2017.

PUGLIESI, G.; DA SILVA, A.G.; VIANA, J.H.M.; SIQUEIRA, L.G.B. Review: Current status of corpus luteum assessment by Doppler ultrasonography to diagnose non-pregnancy and select embryo recipients in cattle. **Animal**, v.17, suppl. 1, 100752, 2023.

REEF, V.B. Fetal Ultrasonography. In: REEF, V.B, Equine Diagnostic Ultrasound. Philadelphia: WB Saunders Co, p.425-445, 1998.

REEF, V.B.; VAALA, W.E.; WORTH, L.T.; SERTICH, P.L.; SPENCER, P.A.; HAMMETT, B. Ultrasonographic evaluation of the fetus and intrauterine environment in the healthy mares during late gestation. **Veterinary Radiology & Ultrasound**, v.36, n.6, p.533-541, 1995.

RENAUDIN, C.D.; TROEDSSON, M.H.T.; GILLIS, C.L. Transrectal ultrasonographic evaluation of normal equine placenta. **Equine Veterinary Education, Newmarket**, v.11, n.2, p.75-76, 1999.

RENAUDIN, C.D.; TROEDSSON, M.H.; GILLIS, C.L.; KING, V.L.; BODENA, A. Ultrasonographic evaluation of the equine placenta by transrectal and transabdominal approach in the normal pregnant mare. **Theriogenology**, v.47, n.2, p.559-573, 1997.

SCALCO, R.; CURCIO, B.R.; Síndrome do mau ajustamento neonatal em potros: foco em neuroesteroides. **Revista Brasileira de Reprodução Animal**, v.45, n.4, p.413-417, 2021.

SIES, H. Oxidative Stress: From Basic Research to Clinical Application. **The American Journal of Medicine**, v.91, (suppl 3C), p.31-38, 1991.

TORIBIO, R.E. Equine Neonatal Encephalopathy: Facts, Evidence and Opinions. **Veterinary Clinics of North America. Equine Practice**, v.35, n.2, p.363-378, 2019.

TROEDSSON, M.H.T.; RENAUDIN, C.D.; ZENT, W.W.; STEINER, J.V. Transrectal ultrasonography of the placenta in normal mares and mares with pending abortion: A field study. **Proceedings of the Annual Convention of American Association of Equine Practitioners**, v.43, p.256-258, 1997.

VAJDOVICH, P. Use of Free Radicals and Antioxidants in Inflammatory Processes of Animals. In: MANDELKER, L. VAJDOVICH, P. **Oxidative Stress in Applied Basic Research and Clinical Practice: Studies on Veterinary Medicine**. 2011<sup>th</sup> edition. Humana Press, New York, 2011. p.19-50.

VASCONCELOS, S.M.L.; GOULART, M.O.F.; MOURA, J.B.F.; MANFREDINI, V.; BENFATO, M.S.; KUBOTA, L.T. Espécies reativas de oxigênio e de nitrogênio, antioxidantes e marcadores de dano oxidativo em sangue humano: principais métodos analíticos para sua determinação. **Química Nova**, v.30, n.5, p.1323-1338, 2007.

ZHANG, J.; WANG, X.; VILLASH, V.; YE, Q.; WU, D.; LIU, Y.; DONG, W. ROS and ROS-Mediated Cellular Signaling. **Oxidative Medicine and Cellular Longevity**, 4350965, 2016.

## **2. CAPÍTULO 2**

Spectral-Doppler evaluation of uterine artery hemodynamics in pregnant mares: a comparative study of normal and abnormal pregnancies and parturition during the last two weeks prepartum

## **Abstract**

Pregnancy is a dynamic process susceptible to various complications that can jeopardize the health of both the mare and the fetus. Utilizing Spectral-Doppler evaluation of uterine artery hemodynamics, our study aimed to assess and compare pulsatility index (PI) and resistance index (RI) values during the last two weeks prepartum in pregnant Brazilian Sport Horse crossbred mares. Nine mares, aged 5 to 21 years, were included in this prospective cohort study. They were divided into normal pregnancy (NP) or abnormal pregnancy (AP) groups based on clinical and ultrasonographic findings indicative of gestational abnormalities. This study evaluated PI and RI indices through Spectral-Doppler examination of the uterine artery ipsilateral to the pregnant horn during the last two weeks prepartum. At the end of the study period, five mares were allocated in the NP group and four mares were allocated in the AP group. PI values decreased ( $P < 0.05$ ) in the NP group between weeks 2 and 1 prepartum, while no significant changes were observed in the AP group. Despite the complications found in the AP group, no significant differences were found in Doppler indices between groups ( $P > 0.05$ ). Further research is warranted to establish physiological parameters for PI and RI indices during the last weeks prepartum and explore the impact of placental diseases and parturition complications on hemodynamic parameters in late-stage equine pregnancies. This study provided important data regarding the uterine hemodynamic changes during the last two weeks of pregnancy and shows the potential of Doppler indices as biomarkers of the gestational health.

**Keywords:** equine; Doppler; pulsatility index; resistance index

## 2.1. Introduction

Pregnancy constitutes a highly dynamic process, and the health of both the pregnant mare and the fetus can be jeopardized by many conditions. High-risk pregnancies can be classified based on their origin: maternal, fetal, or placental, though these categories are not absolute (Juffo et al., 2022).

Episodes of hypoxia, infections, and impaired uterine development are responsible for significant harm to neonatal survival. Each of these conditions, whether occurring alone or in combination, can lead to abortions, premature births, fetal death, and developmental abnormalities in neonates (Bucca et al, 2006). Major contributors to pregnancy loss or complications in the last trimester encompass microbiological agents, placental, fetal and structural abnormalities such as abdominal hernias and prepubic tendon rupture, in addition to systemic diseases (Hong et al., 1993; Chenier & Whitehead, 2009; Pazinato et al., 2017).

Ultrasonographic examination stands as one of the most important tools for non-invasive assessment in modern equine medicine and have been widely integrated into clinical and reproductive practice research. B-mode scanning allows the assessment of static tissues through a grayscale image, being employed specially to evaluate anatomical structures. In contrast, Doppler-mode scanning permits real-time assessment of hemodynamic indices (Nelson & Pretorius, 1988) and provides valuable data for establishing physiological parameters and diagnosing illnesses in horses (Welch et al., 1992; Cipone et al., 1997; Warmerdam, 1998; Siwinska et al., 2021).

The spectral (or pulsed) Doppler mode graphically displays blood flow measurements through objective indices (Nelson & Pretorius, 1988) and is routinely employed in human obstetrics due to its minimal effects and cost-effectiveness, aiding in the assessment of normal and abnormal pregnancies in women (Parra-Cordero et al., 2013; Ridding et al.; Velauthar et al., 2014; Stridsklev et al., 2017). This technique allows the detection of conditions such as preeclampsia, intrauterine growth restriction, and the determination of gestational prognosis (Habberman et al., 2004; Li et al., 2014; Bennasar et al., 2017; Gyselaers et al., 2019). In large animal obstetrics, the method has already been employed to evaluate pregnancy and placental development in sheep, goats, cows, mares, and jennies (Bollwein et al., 2002; Panarace et al., 2006; Beltrame et al.; Elmetwally & Bollwein; Lemos et

al., 2017; Abdelnaby et al.; Campos et al., 2022). However, few studies reporting Doppler indices in abnormal pregnancies are available. Therefore, the objective of this study is to evaluate and compare RI and PI Doppler indices of pregnant mares with normal and abnormal pregnancies during the last two weeks prepartum.

## **2.2. Materials and methods**

### 2.2.1. Animals and location

A prospective cohort study was conducted from October to November 2022 at the Núcleo de Reprodução Equina of the Regimento de Cavalaria Alferes Tiradentes of the Military Police of Minas Gerais, located in Florestal, Minas Gerais state, Brazil (Lat: -19.8866S, Lon: -44.4321W). Nine pregnant Brazilian Sport Horse crossbred mares, aged between 5 and 21 years, weighing between 500 and 700 kg and without previous reproductive history were included in this study. The mares were housed in a paddock, with a diet based on 8 kg of Tifton 85 hay (*Cynodon* spp.) and 4kg of feed (GuabiTech Beet, Guabi Nutrição e Saúde Animal S.A, Brazil) per animal per day. Water and mineral supplement appropriated to the species were offered *ad libitum* throughout the experimental period. All mares were bred, through hand mating, with two Brazilian Sport Horses crossbred stallions.

### 2.2.2. Combined thickness of the uterus and placenta evaluation

Transrectal ultrasound scanning was performed every 48 hours, starting at 320 days of pregnancy until parturition using a Doppler Ultrasound (Z50 Vet, Mindray, China) equipped with a multifrequency linear transducer (5-10 MHz). The examinations were conducted in standing, unsedated animals. B-mode examination was employed to assess the combined thickness of the uterus and placenta (CTUP). The technique used was described by Renaudin et al. (1997), in which the linear transducer was positioned cranially to the cervical star, and then lateralized until the detection of a major uterine vessel. CTUP values were obtained through the average of three measurements between the uterine vessel and allantoic fluid.

### 2.2.3. Spectral-Doppler evaluation

Spectral-Doppler was performed to determine the resistance (RI) and pulsatility (PI) indices of the uterine artery ipsilateral to the gravid uterine horn. The measurement site was located caudally to the uteroplacental junction and a transverse section was used to obtain RI and PI. The indices were calculated based on the average values observed over three consecutive cardiac cycles with similar graphs (Afrakhteh et al., 2014).

#### 2.2.4. Group design

Mares were identified from letters A to I and were allocated after the study period in the normal pregnancy (NP) or abnormal pregnancy (AP) groups. The classification of the mares was based on clinical and/or ultrasonographic signs of gestational abnormality.

#### 2.2.5. Statistical analysis

Statistical analyses were carried out using the Statistical Package for Social Science (SPSS) software 27 (IBM, United States of America). The data were categorized into week 1 (from D-1, being D0 the day of parturition, to D-7) and week 2 (D-8 to D-14) for all variables. Normality of quantitative variables was assessed through the Shapiro-Wilk test. Comparison of CTUP, PI and RI values between weeks 1 and 2 within each group was made using Wilcoxon test. Additionally, the comparison of CTUP, PI and RI values between groups was assessed utilizing the Mann-Whitney U test. Significance level was set at  $P < 0.05$ .

### 2.3. Results

#### 2.3.1. Experimental groups

At the end of the study period, five mares were allocated in the NP group (mares A, B, C, F and G) and four mares were allocated in the AP group (D, E, H and I). Clinical and ultrasonographic findings used as criteria to classified pregnancies as normal or abnormal are summarized in table 1. Etiological causes for abnormalities presented by mares E, H and I were not established.

**Table 1.** Gestational and parturition abnormalities, clinical and ultrasonographic (US) signs exhibited by the mares allocated in the abnormal pregnancy (AP) group.

<b>Mare</b>	<b>Gestational and/or parturition abnormality</b>	<b>Clinical/ US findings</b>
<b>D</b>	Dystocia at 334 days of pregnancy	Fetal expulsion stage longer than 20 minutes without evidence of the fetus
<b>E</b>	Placentitis at 9 months of pregnancy and premature placental separation (“red bag delivery”)	Increased CTUP measurement and fetal fluids echogenicity
<b>H</b>	Placentitis at 10 months of pregnancy; twin pregnancy	Brown vaginal discharge and premature udder development; increased CTUP measurement and fetal fluids echogenicity
<b>I</b>	Placentitis at 356 days of pregnancy	Purulent vaginal discharge; increased echogenicity of fetal fluids

### 2.3.2. Gestational length and combined thickness of uterus and placenta

All mares included in this study successfully carried the pregnancy to term (>320 days), with gestational lengths ranging between 322 and 357 days. Mean CTUP values in weeks 1 and 2 are shown in table 2. Within the NP group, CTUP values showed a significant increase in week 1 compared to week 2 ( $P = 0.04$ ). Conversely, the AP group exhibited no significant differences in CTUP values between weeks ( $P > 0.05$ ). When comparing NP and AP groups, no significant differences were observed in either week 1 or week 2 ( $P > 0.05$ ).

**Table 2.** Mean CTUP values ( $\pm$  SD) in weeks 1 and 2 before parturition for NP and AP groups. Means and SD followed by different superscript letters on the same line indicate difference between them ( $P < 0.05$ ) by the Wilcoxon test.

CTUP measurements (in mm)	Week 1	Week 2
<b>NP group</b>	8.80 $\pm$ 0.53 <sup>a</sup>	7.72 $\pm$ 0.55 <sup>b</sup>
<b>AP group</b>	12.01 $\pm$ 5.11	7.31 $\pm$ 0.91

<sup>a, b</sup> Means  $\pm$  SD followed by different superscript letters on the same line indicate difference between them ( $P < 0.05$ ) by the Wilcoxon test.

### 2.3.3. PI and RI indices

PI and RI mean values for weeks 1 and 2 for NP and AP groups are shown in table 3. In the NP group, PI values exhibited a significant decrease between weeks 2 and 1 ( $P = 0.04$ ). However, RI values did not undergo significant changes between the two weeks ( $P > 0.05$ ). For the AP group, there was no significant differences in PI or RI values from week 2 to 1 ( $P > 0.05$ ). Between the NP and AP groups, no statistical differences were found between RI or PI values in weeks 1 or 2 ( $P > 0.05$ ).

**Table 3.** Mean pulsatility (PI) and resistance index (RI) values ( $\pm$  SD) in weeks 1 and 2 before parturition for NP and AP groups.

Doppler indices	PI week 1	PI week 2	RI week 1	RI week 2
<b>NP group</b>	0.95 $\pm$ 0.16 <sup>a</sup>	1.31 $\pm$ 0.16 <sup>b</sup>	0.54 $\pm$ 0.06	0.61 $\pm$ 0.03
<b>AP group</b>	0.94 $\pm$ 0.20	1.40 $\pm$ 0.04	0.48 $\pm$ 0.03	0.60 $\pm$ 0.04

<sup>a, b</sup> Means  $\pm$  SD followed by different superscript letters on the same line indicate difference between them ( $P < 0.05$ ) by the Wilcoxon test.

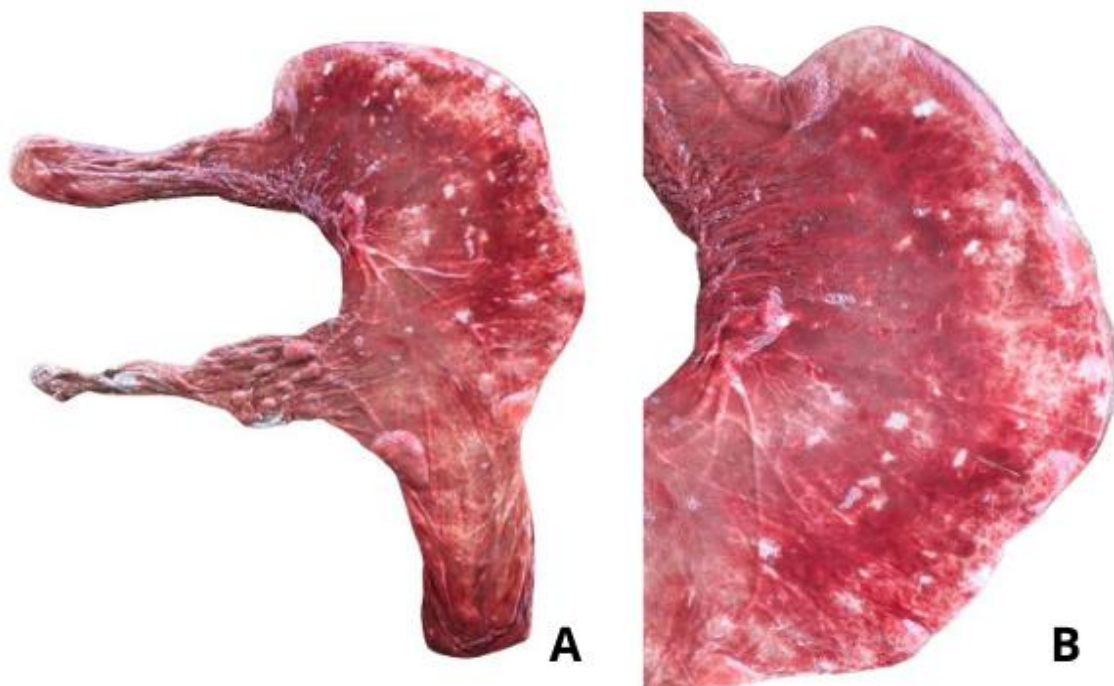
### 2.3.4. Fetal membranes expulsion

All mares in the NP group underwent uneventful expulsion of fetal membranes within 3 hours postpartum. In the AP group, mares E and I also expelled the fetal membranes up to 3 hours after parturition, and mares D and H experienced total or partial fetal membrane retention. Mare D, which experienced premature placental separation, expelled the fetal membranes spontaneously 6 hours postpartum. At

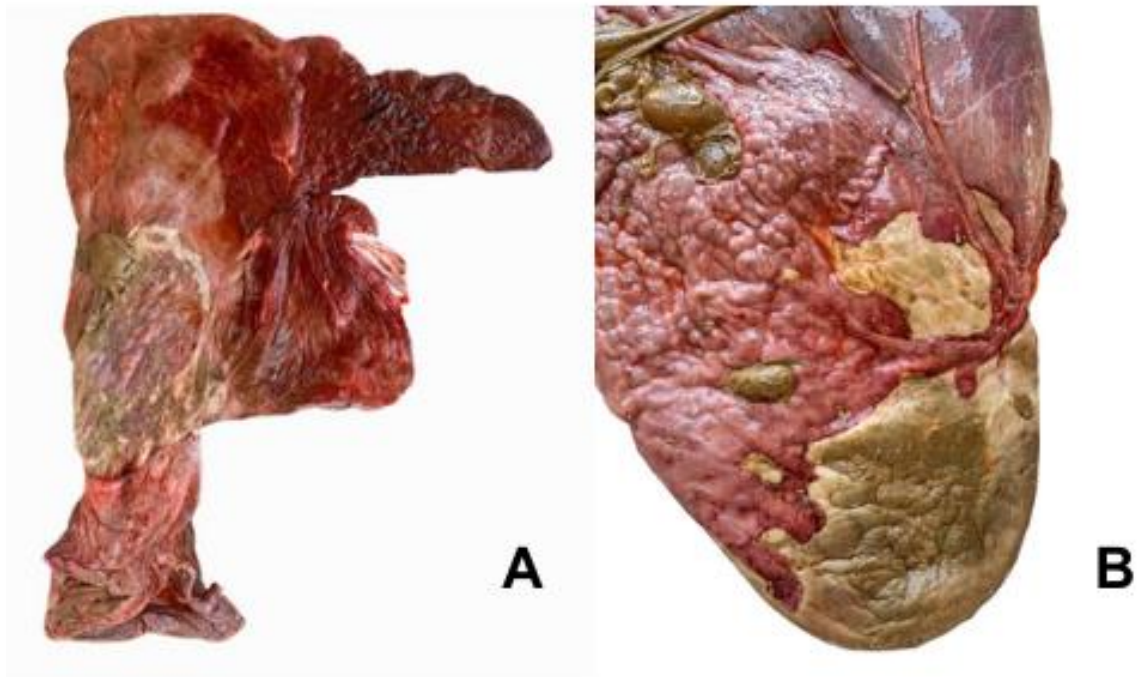
gross examination of the placenta, the chorioallantois was thickened, and the chorionic surface of the pregnant horn, uterine bifurcation and cervical star pole showed extensive hemorrhagic lesions (Fig 1A and 1B). No significant abnormalities were noted in the allantoic surface.

Mare H expelled most part of the fetal membranes spontaneously within 3 hours after foaling and experienced partial placental retention due to a tear at the tip of the pregnant horn. At visual inspection, the chorionic surface of the non-pregnant horn, base of the pregnant horn and uterine bifurcation showed extensive hemorrhagic lesions. Multiple green/brown discoloration spots and exudate build up were observed at the uterine body and cervical star pole (Fig 2A). At the allantoic surface, the tip of the non-pregnant horn was affected, and extensive exudate build up was noted, with multiple necrotic lesions at its perimeter (Fig 2B).

**Fig 1A and 1B.** Chorionic surface of the placenta of mare D, which experienced premature placental separation overall thickening of the chorioallantois, intense deep red color at the pregnant horn, uterine bifurcation and cervical star pole, indicating hemorrhagic lesions



**Fig 2.** Placenta expelled by mare H, which exhibited clinical and ultrasonographic signs of placentitis at 10 months of pregnancy, before the study period, and was diagnosed with a twin pregnancy at parturition; **(A)** chorionic surface of the placenta; non-pregnant horn base of the pregnant horn and uterine bifurcation presenting extensive hemorrhagic lesions; green/brown discoloration and exudate build up at the uterine body and cervical star pole; **(B)** allantoic surface of the non-pregnant horn; severe exudate build up at the tip of the non-pregnant horn, with multiple necrotic lesions at its perimeter



## 2.4. Discussion

The gestational length of all mares in both groups were in agreement to normal values for the equine species (Davies Morel et al., 2002; Aoki et al., 2013) and all CTUP measurement averages in this study were consistent with those reported by Renaudin et al. (1997) for the corresponding gestational and were close to those in Thoroughbred mares (Colón, 2008), breed from which the Brazilian Sport Horse originates. Our results showed a significant increase in CTUP values from week 2 to 1 in the NP group, but the number of animals enrolled in this study must be taken into consideration to interpret the clinical relevance of this statistical finding.

However, mare H (AP group) exhibited CTUP measurements above normal range two days before foaling (17.9 mm) and the occurrence of such a discrepant value had a direct influence on the value found for standard deviation presented by the AP group during week 1. As shown in table 1, this mare had exhibited clinical

and ultrasonographic signs of placentitis and placental dysfunction before the study period. Abnormal increase of CTUP and fetal fluids echogenicity in late pregnancy have been associated with placentitis and pending abortion (Reef et al., 1996; Troedsson et al., 1997; Bucca et al., 2005; Canisso et al., 2015).

Placental infection and edema, among other causes, such as dystocia and obstetric manipulation, are directly associated with a higher incidence of fetal membrane retention when compared to mares with normal pregnancies and parturition (Vandeplassche et al., 1971; Threlfall, 2011). Mares D and H experienced total and partial retention of fetal membranes, respectively, being the most common postpartum problem in the mare (Frazer, 2003). The optimal timeframe for the passage of fetal membranes is not unanimous among reports, but fetal membranes can be considered retained if it is not expelled within 3 hours after foaling (Frazer, 2003; LeBlanc, 2008; Cuervo-Arango & Newcombe, 2009; Threlfall, 2011).

Regarding the uteroplacental perfusion evaluation, our results for PI and RI values in the NP group followed were similar to those reported by Ousey et al. (2012), Bailey et al. (2012a) and Klweitz et al. (2015) for the same time period. Differently from these reports, our PI results showed a significant decrease from week 2 to 1 in the NP group, suggesting an important decrease in blood flow resistance. However, the mean values and standard deviation presented by the NP group in the two weeks are very similar to the values presented by the mares in the AP group for the same period. Therefore, the existence of significance may be a result of the statistical method used to analyze the data.

However, it is important to notice that both indices showed a decrease in their values from week 2 to week 1. One possible explanation for this observation could be a drop in vascular resistance due to the increase in estrogen production. Close to term, the increasing circulating cortisol levels contribute to the production of  $17\beta$ -estradiol (Fowden et al., 2008). Previous studies reported the role of  $17\beta$ -oestradiol as a stimulant for vasodilator prostaglandins (Tostes et al., 2000; Lima et al., 2005) and the vasodilation of the uterine artery during this period could be sufficient to reduce vascular resistance.

The absence of significant differences in both indices between NP and AP groups were consistent with the results reported by Bailey et al. (2012b), where experimentally induced placentitis in pony mares did not induce significant changes in artery blood flow. A decrease in fetal perfusion due to placental dysfunction could

lead to the compensatory secretion of vascular endothelial growth factor (VEGF) by the affected foal, an important stimulating factor of angiogenesis and vasodilatation, in response to hypoxia, as already reported in humans, sheep and pigs (Cheung et al., 1995; Charnock-Jones et al., 2001; 2004).

## 2.5. Conclusion

This is the first study carried out with the objective of assessing hemodynamic indices in Brazilian Sport Horse crossbred mares during the last two weeks of pregnancy. The evaluation of the uteroplacental perfusion using pulsatility and resistance indices represents an opportunity to not only determine physiological parameters during the gestational period, but also to provide valuable information about the quality of the fetal environment. Due to the low number of animals involved in this study, in both groups, and lack of additional information regarding the abnormal cases, only a few observations could be made. In our study, no significant differences were observed in PI and RI values presented by mares with normal pregnancies and parturition and mares who presented gestational and parturition abnormalities during the last two weeks of pregnancy. No differences were found between weeks in the mares which presented abnormalities, but a difference was found between weeks for PI values in the healthy pregnancy group. However, we suggest that this represents only a statistical finding with no clinical relevance. Additional studies are necessary to establish normal parameter for Doppler indices in equine pregnancies and assess the impact of placental diseases and complications during parturition on hemodynamic parameters in the last days of pregnancy.

## 2.6. References

ABDELNABY, E.A.; EMAM, I.A.; EL-SHERBINY, H.R.; FADL, A.M. The effects of aging and gestational month on uteroplacental vascular perfusion, and umbilical artery hemodynamics in pregnant jennies. **BMC Veterinary Research**, v.18, n.1, 2022.

AOKI, T.; YAMAKAWA, K.; ISHII, M. Factors affecting gestation length in Heavy Draft mares. **Journal of Equine Veterinary Science**, v.33, n.6, p.437-440, 2013.

BAILEY, C.S.; HEITZMAN, J.M.; BUCHANAN, C.A.; BARE, C.A.; SPER, R.B.; BORST, L.B.; MACPHERSON, M.; ARCHIBALD, K.; WHITACRE, M. B-mode and Doppler ultrasonography in pony mares with experimentally induced ascending placentitis. **Equine Veterinary Journal**, v.44, n.43, p.88-94, 2012b.

BAILEY, C.S.; SPER, R.B.; SCHEWMAKER, J.L.; BUCHANAN, C.N.; BEACHLER, T.M.; POZOR, M.A.; WHITACRE, M.D. Uterine artery blood flow remains unchanged in pregnant mares in response to short-term administration of pentoxifylline. **Theriogenology**, v.77, n.2, p.430-436, 2012a.

BELTRAME, R. T.; COVRE, C.; LITTIG, L. B.; MARTINS, A. B.; QUIRINO, C. R.; BARTHOLAZZI JUNIOR, A.; DA COSTA, R. L. D. Transrectal Doppler sonography of uterine blood flow in ewes during pregnancy. **Theriogenology**, v.91, p.55-61, 2017.

BENNASAR, M.; EIXARCH, E.; MARTINEZ, J. M.; GRATACÓS, E. Selective intrauterine growth restriction in monochorionic diamniotic twin pregnancies. **Seminars in Fetal & Neonatal Medicine**, v.22, n.6, p.376-382, 2017.

BOLLWEIN, H.; BAUMGARTNER, U.; STOLLA, R. Transrectal Doppler sonography of uterine blood flow in cows during pregnancy. **Theriogenology**, v.57, n.8, p.2053-2061, 2002.

BOENING, K.J.; LEENDERTSE, I.P. Review of 115 cases of colic in the pregnant mare. **Equine Veterinary Journal**, v.25, n.6, p.518-521, 1993.

BOLLWEIN, H.; MAIERL, J.; MAYER, R.; STOLLA, R. Transrectal color Doppler sonography of the A. uterine in cyclic mares. **Theriogenology**, v.49, n.8, p.1483-1488, 1998.

BUCCA, S.; FOGARTY, U.; COLLINS, A.; SMALL, V. Assessment of feto-placental well-being in the mare from mid-gestation to term: transrectal and transabdominal ultrasonographic features. **Theriogenology**, v.64, n.3, p.542-557, 2005.

CAMPOS, I. S.; DE SOUZA, G. N.; GOMES, G. M.; PINNA, A. E.; FERREIRA, A. M. R. Spectral Doppler ultrasound in the placental development of Mangalarga Marchador mares. **Theriogenology**, v.180, p.171-175, 2022.

CANISSO, I.F.; BALL, B.A.; EROL, E.; SQUIRES, E.L.; TROEDSSON, M. Comprehensive review on equine placentitis. **Proceedings of the American Association of Equine Practitioners**, v.61, p.490-509, 2015.

CHARNOCK-JONES, D.S.; CLARK, D.E.; LICENCE, D.; DAY, K.; WOODING, F.B.; SMITH, S.K. Distribution of vascular endothelial growth factor (VEGF) and its binding sites at the maternal-fetal interface during gestation in pigs. **Reproduction**, v.122, n.5, p.753-760, 2001.

CHARNOCK-JONES, D.S.; KAUFMANN, P.; MAYHEW, T.M. Aspects of Human Fetoplacental Vasculogenesis and Angiogenesis. I. Molecular regulation. **Placenta**, v.35, n.2-3, p.103-113, 2004.

CHENIER, T.S.; WHITEHEAD, A.E. Foaling rates and risk factors for abortion in pregnant mares presented for medical or surgical treatment of colic: 153 cases (1993-2005). **The Canadian Veterinary Journal**, v.50, n.5, p.481-485, 2009.

CHEUNG, C.Y.; SINGH, M.; EBAUGH, M.J.; BRACE, R.A. Vascular endothelial growth factor gene expression in ovine placenta and fetal membranes. **American Journal of Obstetrics and Gynecology**, v.173, n.3, p.753-759, 1995.

CIPONE, M.; PIETRA, M. GANDINI, G.; BOARI, A.; GUGLIELMINI, C.; VENTUROLI, M. Pulsed wave-Doppler ultrasonographic evaluation of the common carotid artery in the resting horse: physiologic data. **Veterinary Radiology & Ultrasound**, v.38, n.6, p.200-206, 1997.

COLÓN, J.L. Trans-Rectal Ultrasonographic Appearance of Abnormal Combined Utero-Placental Thickness in Late-Term Gestation and its Incidence During Routine Survey in a Population of Thoroughbred Mares (2005-2008). **Proceedings of the American Association of Equine Practitioners**, v.54, p.279-285, 2008.

CUERVO-ARANGO, J.; NEWCOMBE, J.R. The Effect of Manual Removal of Placenta Immediately after Foaling on Subsequent Fertility Parameters in the Mare. **Journal of Equine Veterinary Science**, v.29, n.11, p.771-774, 2009.

DAVIES MOREL, M.C.G.; NEWCOMBE, J.R.; HOLLAND, S.J. Factors affecting gestations length in the Thoroughbred mare. **Animal Reproduction Science**, v.74, n.3-4, p.175-185, 2002.

ELMETWALLY, M.; BOLLWEIN, H. Uterine blood flow in sheep and goats during the peri-parturient period assessed by transrectal Doppler sonography. **Animal Reproduction Science**, v.176, p.32-39, 2017.

FRAZER, G.S. *Post partum* complications in the mare. Part 2: Fetal membrane retention and conditions of the gastrointestinal tract, bladder and vagina. **Equine Veterinary Education**, v.15, n.2, p.91-100, 2003.

FOWDEN, A.L.; FORHEAD, A.J.; OUSEY, J.C. The Endocrinology of equine parturition. **Experimental and Clinical Endocrinology & Diabetes**, v.116, n.7, p.393-403, 2008.

GYSELAERS, W.; VONCK, S.; STAELENS, A. S.; LANSSENS, D.; TOMSIN, K.; OBEN, J.; DREESEN, P.; BRUCKERS, L. Gestational hypertensive disorders show unique patterns of circulatory deterioration with ongoing pregnancy. **American Journal of Physiology: Regulatory, Integrative & Comparative Physiology**, v.316, n.3, p.210-221, 2019.

HABBERMAN, S.; BRACERO, L. A.; BRYNE, D. W. Spectral Doppler index mapping of the umbilicoplacental circulation and pregnancy outcome. **Gynecologic and Obstetric Investigation**, v.58, n.1, p.1-7, 2004.

HONG, C.B.; DONAHUE, J.M.; GILES JR., R.C.; PETRITES-MURPHY, M.B.; POONACHA, K.B.; ROBERTS, A.W.; SMITH, B.J.; TRAMONTIN, R.R.; TUTTLE, P.A.; SWERCZEK, T.W. Etiology and pathology of equine placentitis. **Journal of Veterinary Diagnostic Investigation**, v.5, n.1, p.56-63, 1993.

LEMOS, S.G.C.; CAMPOS, D.G.; FERREIRA, C.S.C.; BALARO, M.F.A.; CUNHAA, L.E.R.; PINNA, A.E.; BRANDÃO, F.Z. Vascularização uterina de éguas prenhes de jumento e de garanhão monitoradas por ultrassonografia Doppler. **Pesquisa Veterinária Brasileira**, v.37, n.8, p.877-882, 2017.

LI, N.; GHOSH, G.; GUDMUNDSSON, S. Uterine artery Doppler in high-risk pregnancies at 23-24 gestational weeks is of value in predicting adverse outcomes of pregnancy and selecting cases for more intense surveillance. **Acta Obstetrica et Gynecologica Scandinavica**, v.93, n.12, p.1276-1281, 2014.

LIMA, S.M.R.R.; ALDRIGHI, J.M.; CONSOLIM-COLOMBO, F.M.; MANSUR, A.P.; RUBIRA, M.C.; KRIEGER, E.M.; RAMIRES, J.A.F. Acute administration of 17beta-estradiol improves endothelium-dependent vasodilation in postmenopausal women. **Maturitas**, v.50, n.4, p.266-274, 2005.

NELSON, T.R.; PRETORIUS, D.H. The Doppler Signal: Where Does It Come From and What Does It Mean?. **American Journal of Roentgenology**, v.151, n.3, p.439-447, 1988.

OUSEY, J.C.; KÖLLING, M.; NEWTON, R.; WRIGTH, M.; ALLEN, W.R. Uterine haemodynamics in young and aged pregnant mares measured using Doppler ultrasonography. **Equine Veterinary Journal. Supplement**, v.41, p.15-21, 2012.

PANARACE, M.; GARNIL, C.; MARFIL, M.; JAUREGUI, G.; LAGIOIA, J.; LUTHER, E.; MEDINA, M. Transrectal Doppler sonography for evaluation of uterine blood flow throughout pregnancy in 13 cows. **Theriogenology**, v.66, n.9, p.2113-2119, 2006.

PARRA-CORDERO, M.; RODRIGO, R.; BARJA, P.; BOSCO, C.; RENCORET, G.; SEPÚLVEDA-MARTINEZ, A.; QUEZADA, S. Prediction of early and late preeclampsia from maternal characteristics, uterine artery Doppler and markers of vasculogenesis during the first trimester of pregnancy. **Ultrasound in Obstetrics & Gynecology**, v.41, n.5, p.538-544, 2013.

PAZINATO, F.M.; CURCIO, B.R.; FERNANDES, C.G.; SANTOS, C.A.; FEIJÓ, L.S.; VARELA, A.S.; NOGUEIRA, C.E.W. Histomorphometry of the placental vasculature

and microcotyledons in Thoroughbred mares with chronic liminitis. **Theriogenology**, v.91, p.77-81, 2017.

REEF, V.B.; VAALA, W.E.; WORTH, L.T.; SERTICH, P.L.; SPENCER, P.A. Ultrasonographic assessment of fetal well-being during late gestation: development of an equine biophysical profile. **Equine Veterinary Journal**, v.28, n.3, p.200-208, 1996.

RENAUDIN, C.D.; TROEDSSON, M.H.; GILLIS, C.L.; KING, V.L.; BODENA, A. Ultrasonographic evaluation of the equine placenta by transrectal and transabdominal approach in the normal pregnant mare. **Theriogenology**, v.47, n.2, p.559-573, 1997.

RIDDING, G.; SCHLUTER, P.J.; HYETT, J.A.; MCLENNAN, A.C. Uterine artery pulsatility index assessment at 11-13 week's gestation. **Fetal Diagnosis & Therapy**, v.36, n.4, p.299-304, 2014.

SIWINSKA, N.; ZAK, A.; SLOWIKOWSKA, M.; PASLAWSKA, U. Renal Resistive Index as A Potential Indicator of Acute Kidney Injury in Horses. **Journal of Equine Veterinary Science**, v.103, 103662, 2021.

STRIDSKLEV, S.; SALVESEN, O.; SALVESEN, K.; CARLSEN, S.M.; HUSOY, M.A.; VANKY, E. Uterine artery Doppler measurements during first and second trimesters of normal pregnancy. **Acta Obstetrica et Gynecologica Scandinavica**, v.96, n.3, p.366/371, 2017.

THRELFALL, W.R. Retained Fetal Membranes. In: MCKINNON, A.O.; SQUIRES, E.L.; VAALA, W.E.; VARNER, D.D. **Equine Reproduction**. 2nd edition. Chichester: Wiley-Blackwell, 2011. p.2520-2529.

TOSTES, R.C.; NIGRO, D.; FORTES, Z.B.; CARVALHO, M.H.C. Effects of oestrogen on the vascular system. **Brazilian Journal of Medical and Biological Research**, v.36, p.1143-1158, 2000.

TROEDSSON, M.H.T.; RENAUDIN, C.D.; ZENT, W.W.; STEINER, J.V. Transrectal Ultrasonography of the Placenta in Normal Mares and Mares with Pending Abortion:

A Field Study. Proceedings of the American Association of Equine Practitioners, v.43, p.256-258, 1997.

VANDESPASSCHE, M.; SPINCEMAILLE, J.; BOUTERS, R. Aetiology, pathogenesis and treatment of retained placenta in the mare. **Equine Veterinary Journal**, v.3, n.4, p.144-147, 1971.

VELAUTHAR, L.; PLANA, M.N.; KALIDINDI, M.; ZAMORA, J.; THILAGANATHAN, B.; ILLANES, S.E.; KHAN, K.S.; AQUILINA, J.; THANGARATINAM, S. First-trimester uterine artery Doppler and adverse pregnancy outcome: a meta-analysis involving 55,974 women. **Ultrasound in Obstetrics & Gynecology**, v.43, n.5, p.500-507, 2014.

WARMERDAM, E.P. Ultrasonography of the femoral artery in six normal horses and three horses with thrombosis. **Veterinary Radiology & Ultrasound**, v39, n.2, p.137-141, 1998.

WELCH, R.D.; DEAN, P.W.; MILLER, M.W. Pulsed spectral Doppler evaluation of a peripheral arteriovenous fistula in a horse. **Journal of the American Veterinary Medical Association**, v.200, p.1360-1362, 1992.

### **3. CAPÍTULO 3**

Oxidative stress in equine pregnancy and parturition: a comparative study of blood and placental markers in normal and abnormal cases during the last two weeks prepartum

## **Abstract**

The maintenance of redox balance is crucial for cellular homeostasis, with redox pairs orchestrating the exchange of electrons in many physiological processes. Pregnancy itself can be considered a state of oxidative stress, as the pregnant mare is under great pressure of energy demand by the growing fetus. This study investigates and compares the oxidative status of pregnant mares with healthy pregnancies and those experiencing gestational abnormalities and/or parturition complications during the last two weeks before parturition, categorizing them as normal or abnormal based on clinical and ultrasonographic parameters. Nine Brazilian Sport Horse crossbred mares, aged 5 to 21 years, were included in this prospective cohort study. B-mode scanings were conducted every 48 hours for CTUP determination and blood samples were obtained daily from day 320 of pregnancy until parturition. Three samples were collected from each placenta up to 6 hours after parturition. Oxidative stress markers quantification and enzymatic activity were determined by 5 assays through spectrophotometry: (1) CAT activity, (2) SOD activity, (3) FRAP, (4) protein carbonyl quantification, and (5) MDA determination. Results revealed significant differences in blood MDA levels between normal and abnormal pregnancies, but other markers showed no differences between weeks or groups. This study provides valuable insights into equine oxidative status during pregnancy and calls for further research using a larger number of animals to identify potential biomarkers for placental diseases in late-stage equine pregnancies.

**Keywords:** Enzymatic activity; oxidative stress markers; pregnant mare

### 3.1. Introduction

The maintenance of redox balance in cells, tissues, and biological fluids is orchestrated by redox pairs that undergo continual exchange of electrons, transitioning between oxidized and reduced states. This dynamic equilibrium is sustained by the physiological and ongoing formation of reactive species, stemming from cellular aerobic metabolism (Ray et al., 2012). The term "reactive species" encompasses free radicals and includes those lacking unpaired electrons but exhibiting high reactivity due to instability (Nakai e Tsuruta, 2021).

Reactive species participate in normal biochemical reactions, facilitating energy production, activating cellular defense mechanisms during infectious processes, regulating cell growth, senescence, and apoptosis (Zhang et al., 2016). However, excessive production can lead oxidative damage, disrupting cellular homeostasis to varying degrees. Accumulation of reactive species can result in biomolecule oxidation, including lipid peroxidation, protein damage, carbohydrate oxidation, and RNA destruction, as well as damage to mitochondrial and nuclear DNA (Pizzino et al., 2017). In order to eliminate or modify the structure of reactive species and mitigate their harmful effects, the organism possesses enzymatic and non-enzymatic antioxidant systems that operate through different mechanisms. Molecules with antioxidant capacity can be synthesized by the organism itself or obtained through the diet (Sies, 1991). In healthy organisms, the antioxidant system balances the production of reactive species (Zhang et al., 2016).

At normal concentrations, reactive species play crucial roles in various reproductive processes in females, such as ovulation and follicular atresia (Shirai et al., 2002; Tiwari & Chaube, 2016), the formation of the corpus luteum (Sugino, 2005), implantation (Guérin et al., 2001), embryonic growth, the maintenance of pregnancy (Al-Gubory et al., 2012), and parturition (Masumoto et al., 1990; Jenkin & Young, 2004).

Pregnancy itself can be considered a state of oxidative stress, as the pregnant mare is under the pressure of a significant energy demand (Wisdom et al., 1991). Studies by Sgorbini et al. (2015) and Cecchini et al. (2019) highlighted the protective role of the healthy placenta in mares against oxidative damage to the foal by increasing antioxidant system activity. While high oxidative stress is linked to complicated pregnancies in human medicine (Myatt & Cui, 2004), information about

the oxidative status during complicated pregnancies and parturition in mares is currently lacking. The objective of this study is to assess and compare blood and placental oxidative stress markers and enzymatic activity between pregnant mares with healthy pregnancies and parturition and mares who presented gestational abnormalities and/or parturition complications during the last two weeks of pregnancy.

### **3.2. Materials and methods**

#### **3.2.1. Animals and location**

A prospective cohort study was carried out at the Núcleo Equino de Reprodução of the Regimento de Cavalaria Alferes Tiradentes of the Military Police of Minas Gerais located in Florestal, Minas Gerais state, Brazil (Lat: -19.8866S, Lon: -44.4321W), spanning from October to November 2022. Nine pregnant Brazilian Sport Horse crossbred mares, aged between 5 and 21 years, weighing between 500 and 700 kg, and with no prior reproductive history, were included in this study. The mares were accommodated in a paddock and received a diet consisting of 8 kg of Tifton 85 hay (*Cynodon* spp.) and 4kg of feed (GuabiTech Beet, Guabi Nutrição e Saúde Animal S.A, Brazil) per animal per day. Water and mineral supplement were offered *ad libitum* throughout the experimental period. All mares were bred with two Brazilian Sport Horses crossbred stallions through hand mating. The project was submitted and approved by the Ethics Committee Use of Animals (CEUA) of the Federal University of Viçosa filed under registration number 45/2022.

#### **3.2.2. Ultrasonographic examination**

Transrectal ultrasound examination were performed every 48 hours, starting at 320 days of pregnancy and continuing until parturition using a Doppler Ultrasound (Z50 Vet, Mindray, China) equipped with a multifrequency linear transducer (5-10 MHz). All examinations were conducted in standing, unsedated animals. B-mode scanning was employed to measure the combined thickness of the uterus and placenta (CTUP). The technique used was described by Renaudin et al. (1997), in which the linear transducer was positioned cranially to the cervical star, and then

lateralized until the detection of a major uterine vessel. CTUP values were obtained through the average of three measurements between the uterine vessel and allantoic fluid.

### 3.2.3. Experimental groups

Mares were identified from letters A to I and were allocated after the study period in the normal pregnancy (NP) or abnormal pregnancy (AP) groups. The classification of the mares was based on clinical and/or ultrasonographic signs of gestational abnormality.

### 3.2.4. Blood samples

Blood samples were collected daily from 320 days of gestation until parturition day by jugular venipuncture. The collection was performed using vacuum tubes internally coated with a clot activator (Vacuplast, Cralplast, Brazil). The collected samples were promptly subjected to centrifugation at 3.500 x g for 10 minutes and the blood serum was transferred to 1,5 mL Eppendorf tubes. Samples were then stored at -20° C until analysis.

### 3.2.5. Fetal membranes expulsion and placenta samples

Fetal membranes expulsion was timed for every mare and following the expulsion the placentas were arranged in an 'F' formation for evaluation, and the pregnant and non-pregnant uterine horns were identified. Assessment of placental integrity followed, with specific attention to identification of tears and/or partial retention (Christensen; Whitwell, 2011). Sampling was performed in all animals included in this study within 6 hours after foaling. Fragments were obtained from the pregnant (PH) and non-pregnant uterine horns (NPH), and uterine body (B). These samples were stored in 2 mL cryotubes and preserved in liquid nitrogen until the time of analysis.

### 3.2.6. Oxidative stress markers and enzymatic activity

Oxidative stress markers quantification and enzymatic activity was assessed by UV/Vis spectrophotometry (Thermo Scientific Multiskan SkyHigh Microplate Spectrophotometer, Thermo Fisher Scientific, Sweden). The following assays were conducted on the samples: (1) protein carbonyl assay (PC; Levine et al., 1990); (2) malondialdehyde determination assay (MDA; Draper & Hadley, 1990); (3) catalase activity assay (CAT; Aebi, 1984); (4) superoxide dismutase activity assay (SOD; Bannister & Calabrese, 1987) and (5) ferric reducing ability of plasma assay (FRAP; Benzie & Strain, 1996). Placenta samples were also submitted to the Bradford assay (Bradford, 1976) for protein quantification.

Before analysis, each placenta sample (100 mg) was transferred to a 2 ml Eppendorf tube containing 1 ml of phosphate-buffered saline (PBS) solution along with two stainless steel beads. Subsequently, the samples underwent disruption (TissueLyser II, QIAGEN, Germany) at 25 Hz for 5 minutes, until complete tissue disruption was achieved.

### 3.2.7. Statistical Analysis

Statistical analyses were carried out using the Statistical Package for Social Science (SPSS) software 27 (IBM, United States of America) and significance level was set at  $P < 0.05$ . CTUP measurement and results for enzymatic activity and oxidative stress markers were grouped into week 1 (from D-1, with D0 being the day of parturition, to D-7) and week 2 (D-8 to D-14). Normality quantitative variables was assessed through the Shapiro-Wilk test. Continuous variables were compared using the paired-samples T test or the Wilcoxon test, depending on the normality of the data. The variables for placental markers were compared using ANOVA repeated measures or the Friedman test, depending on the normality of the data. Statistical significance was set at  $P < 0.05$  for all variables.

### 3.3. Results

#### 3.3.1. Experimental groups

At the end of the study period, five mares were allocated in the NP group (mares A, B, C, F and G) and four mares were allocated in the AP group (D, E, H and I). Clinical and ultrasonographic findings used as criteria to classified pregnancies as normal or abnormal are summarized in table 1. Etiological causes for abnormalities presented by mares E, H and I were not established.

**Table 1.** Gestational and parturition abnormalities, clinical and ultrasonographic (US) sings exhibited by the mares allocated in the abnormal pregnancy (AP) group.

<b>Mare</b>	<b>Gestational and/or parturition abnormality</b>	<b>Clinical/ US findings</b>
<b>D</b>	Dystocia at 334 days of pregnancy	Fetal expulsion stage longer than 20 minutes without evidence of the fetus
<b>E</b>	Placentitis at 9 months of pregnancy and premature placental separation (“red bag delivery”)	Increased CTUP measurement and fetal fluids echogenicity
<b>H</b>	Placentitis at 10 months of pregnancy; twin pregnancy	Brown vaginal discharge and premature udder development; increased CTUP measurement and fetal fluids echogenicity
<b>I</b>	Placentitis at 356 days of pregnancy	Purulent vaginal discharge; increased echogenicity of fetal fluids

#### 3.3.2. Gestational length and CTUP measurements

All mares included in this study were able to successfully carry the pregnancy to term (>320 days), with gestational lengths ranging between 322 and 357 days. Mean CTUP values in weeks 1 and 2 are shown in table 2. Within the NP, the mean values for CTUP measurements for weeks 2 and 1 indicated a significant increase in the last week before parturition (P = 0.043). In contrast, the AP group exhibited no significant differences in CTUP values between weeks 2 and 1. When comparing

NP and AP groups, no significant differences were observed in either week 1 or week 2.

**Table 2.** mean CTUP values ( $\pm$  SD) in weeks 1 and 2 before parturition for NP and AP groups.

CTUP measurements (in mm)	Week 1	Week 2
<b>NP group</b>	8.80 $\pm$ 0.53 <sup>a</sup>	7.72 $\pm$ 0.55 <sup>b</sup>
<b>AP group</b>	12.01 $\pm$ 5.11	7.31 $\pm$ 0.91

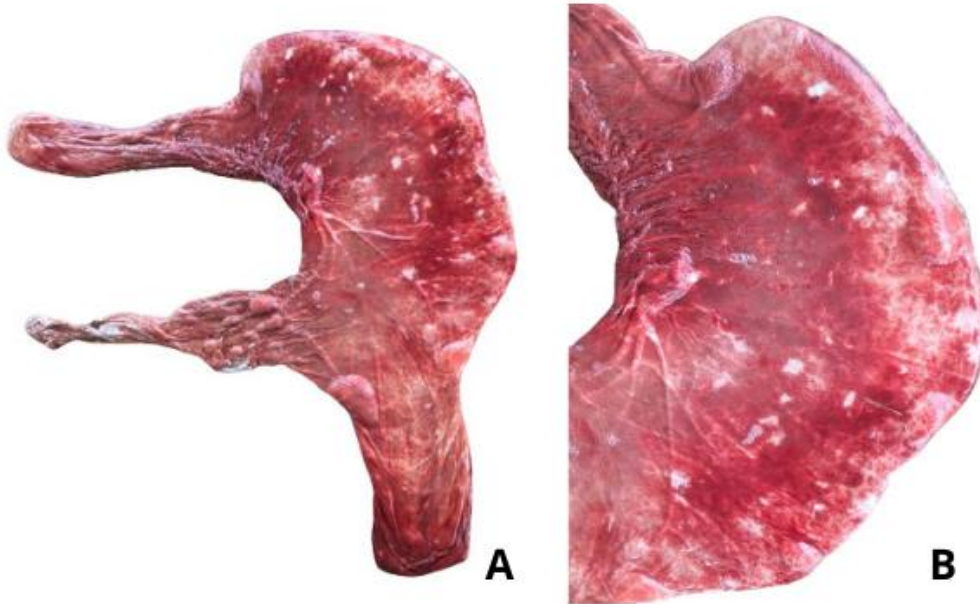
<sup>a,b</sup> Means  $\pm$  SD followed by different superscript letters on the same line indicate difference between them ( $P < 0.05$ ) by the Wilcoxon test.

### 3.3.3. Fetal membranes expulsion

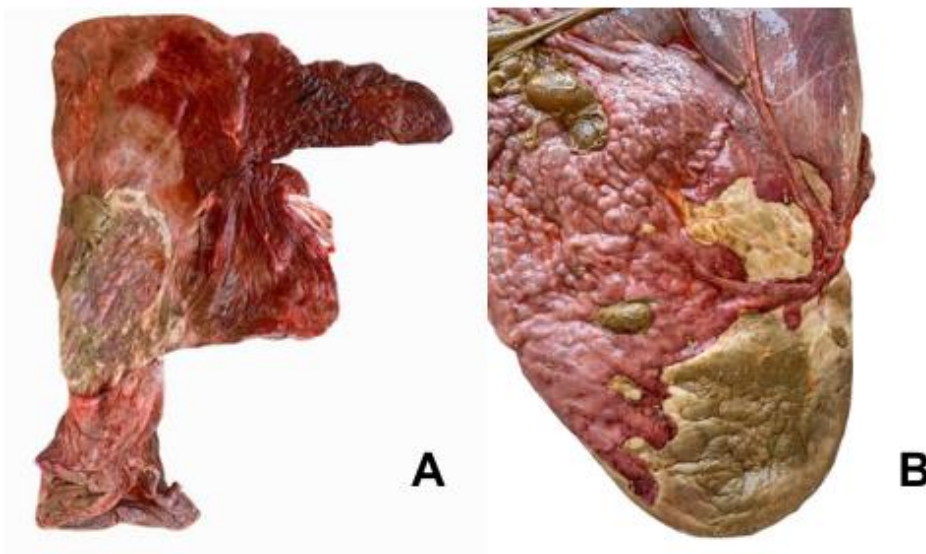
All mares allocated in the NP group spontaneously expelled the fetal membranes within 3 hours after foaling. In the AP group, mares E and I also expelled the fetal membranes spontaneously 3 hours postpartum and mares D and H experienced total or partial fetal membrane retention. Mare D, which experienced premature placental separation, expelled the fetal membranes spontaneously 6 hours postpartum. At gross examination of the placenta, the chorioallantois was thickened, and the chorionic surface of the pregnant horn, uterine bifurcation and cervical star pole showed extensive hemorrhagic lesions (Fig 1A and 1B). No significant abnormalities were noted in the allantoic surface.

Mare H expelled most part of the fetal membranes spontaneously within 3 hours after foaling and experienced partial placental retention due to a tear at the tip of the pregnant horn. At visual inspection, the chorionic surface of the non-pregnant horn, base of the pregnant horn and uterine bifurcation showed extensive hemorrhagic lesions. Multiple green/brown discoloration spots and exudate build up were observed at the uterine body and cervical star pole (Fig 2A). At the allantoic surface, the tip of the non-pregnant horn was affected, and extensive exudate build up was noted, with multiple necrotic lesions at its perimeter (Fig 2B).

**Fig 1A and 1B.** Chorionic surface of the placenta of mare D, which experienced premature placental separation overall thickening of the chorioallantois, intense deep red color at the pregnant horn, uterine bifurcation and cervical star pole, indicating hemorrhagic lesions



**Fig 2.** Placenta expelled by mare I, which exhibited clinical and ultrasonographic signs of placentitis at 10 months of pregnancy, before the study period, and was diagnosed with a twin pregnancy at parturition; **(A)** chorionic surface of the placenta; non-pregnant horn base of the pregnant horn and uterine bifurcation presenting extensive hemorrhagic lesions; green/brown discoloration and exudate build up at the uterine body and cervical star pole; **(B)** allantoic surface of the non-pregnant horn; severe exudate build up at the tip of the non-pregnant horn, with multiple necrotic lesions at its perimeter.



#### 3.3.4. Blood oxidative stress markers and enzymatic activity

There were no significant differences in oxidative stress markers or enzymatic activity evaluated in this study for any of the variables between weeks 2 and 1 for NP and AP groups ( $P > 0.05$ ). When comparing normal and abnormal pregnancies, only MDA values for week 1 showed statistical difference, with higher values in the AP group ( $P = 0.048$ ). Mean values for CAT, SOD, MDA, FRAP and PC for weeks 2 and 1 for AP and NP groups are shown in table 3.

**Table 3.** Mean values ( $\pm$ SD) for blood oxidative stress markers and enzymatic activity for week 2 (WK 2) and week 1 (WK 1; CAT in U/ml; SOD in  $\mu$ mol/ml; MDA in nmol/ml; FRAP in  $\mu$ mol/ml; PC in nmol/ml).

	CAT		SOD		FRAP		PC		MDA	
	Week 2	Week 1	Week 2	Week 1	Week 2	Week 1	Week 2	Week 1	Week 2	Week 1
<b>NP group</b>	43.84 $\pm$ 5.24	43.73 $\pm$ 7.27	18.67 $\pm$ 6.9	18.54 $\pm$ 6.13	8.13 $\pm$ 1.97	8.19 $\pm$ 1.49	69.07 $\pm$ 55.56	104.74 $\pm$ 104.69	73.9 $\pm$ 15.85	53.98 $\pm$ 19.12 <sup>a</sup>
<b>AP group</b>	50.79 $\pm$ 12.88	53.15 $\pm$ 19.42	23.87 $\pm$ 0.53	20,7 $\pm$ 1,81	5.97 $\pm$ 1,19	6.71 $\pm$ 1.08	48.19 $\pm$ 24.41	57.61 $\pm$ 34.47	117.03 $\pm$ 120.96	89.1 $\pm$ 32.86 <sup>b</sup>

<sup>a,b</sup> Means  $\pm$  SD followed by different superscript letters on the same column indicate difference between them ( $P < 0.05$ ) by the Mann-Whitney test.

### 3.3.5. Placenta oxidative stress markers and enzymatic activity

No significant differences were found in oxidative stress markers or enzymatic activity in placenta samples included in this study within the NP and AP groups or between groups ( $P > 0.05$ ). Mean values for CAT, SOD, MDA, FRAP and PC for PH, NPH and B fragments are shown in table 4.

**Table 4.** Mean values ( $\pm$ SD) for oxidative stress markers and enzymatic activity for uterine pregnant horn (PH), non-pregnant horn (NPH) and uterine body (B; CAT in U/ml; SOD in  $\mu$ mol/ml; MDA in nmol/ml; FRAP in  $\mu$ mol/ml; PC in nmol/ml).

	CAT			SOD			FRAP			PC			MDA		
	PH	NPH	B	PH	NPH	B	PH	NPH	B	PH	NPH	B	PH	NPH	B
<b>NP group</b>	44.07 $\pm$ 60.8	46.8 $\pm$ 65.22	45.26 $\pm$ 62.25	78.55 $\pm$ 99.51	37.96 $\pm$ 43.32	35.36 $\pm$ 38.04	0.62 $\pm$ 0.48	0.47 $\pm$ 0.57	0.74 $\pm$ 0.35	4.27 $\pm$ 6.02	3.18 $\pm$ 4.37	3.31 $\pm$ 5.87	29.74 $\pm$ 22.87	16.71 $\pm$ 7.55	30.44 $\pm$ 31.8
<b>AP group</b>	198.99 $\pm$ 295.78	207.21 $\pm$ 352.44	110.56 $\pm$ 134.15	28.99 $\pm$ 8.61	22.27 $\pm$ 6.51	16.49 $\pm$ 5.75	0.35 $\pm$ 0.4	0.55 $\pm$ 0.39	0.64 $\pm$ 0.24	7.13 $\pm$ 5.68	6.11 $\pm$ 5.69	3.82 $\pm$ 4.15	15.1 $\pm$ 6.33	17.02 $\pm$ 14.93	23.93 $\pm$ 4.78

<sup>a,b</sup> Means  $\pm$  SD followed by different superscript letters on the same line indicate difference between them ( $P < 0.05$ ).

### 3.4. Discussion

The gestational length of all mares in both groups fell within normal values for the equine species, as described by Davies Morel et al. (2002) and Aoki et al. (2013). Regarding the ultrasonographic placental structure evaluation, at the statistical analysis, all CTUP average measurements were within normal parameters for the corresponding gestational age, as reported by Renaudin et al. (1997) and were close to those in Thoroughbred mares (Colón, 2008), breed from which the Brazilian Sport Horse originates. Previous studies reported that the age of the mare and gestational length do not affect CTUP measurements in late pregnancy. Our results showed a significant increase in CTUP values from week 2 to 1 in the NP group, but the number low number of animals enrolled in this study must be taken into consideration to interpret the clinical relevance of this finding.

Even though not statistically significant, mare H (AP group) exhibited abnormal CTUP measurements two days before foaling (17,9 mm) and the occurrence of such a discrepant value had a direct influence on the value found for standard deviation presented by the AP group during week 1. As shown in table 1, this mare had exhibited clinical and ultrasonographic signs of placentitis (Troedsson & MacPherson, 2011) and placental dysfunction before the study period. Abnormal increases in CTUP and echogenicity of the fetal fluids in late pregnancy have been associated with placentitis and pending abortion (Reef et al., 1996; Troedsson et al., 1997; Bucca et al., 2005; Canisso et al., 2015).

Placental infection and edema, among other causes, such as dystocia and obstetric manipulation, are directly associated with a higher incidence of fetal membrane retention when compared to mares with normal pregnancies and parturition (Vandeplassche et al., 1971; Threlfall, 2011). Mares D and H experienced total and partial retention of fetal membranes, respectively, being the most common postpartum problem in the mare (Frazer, 2003). The optimal timeframe for the passage of fetal membranes is not unanimous among reports, but fetal membranes can be considered retained if it is not expelled within 3 hours after foaling (Frazer, 2003; LeBlanc, 2008; Cuervo-Arango & Newcombe, 2009; Threlfall, 2011).

Our results followed a similar tendency to pregnant women with placental dysfunction due to preeclampsia (Loverro et al., 1996; Kumar & Das, 2000; Madazli

et al., 2002; Aydin et al., 2004; Halliwell & Gutteridge, 2007; Rani et al., 2010; Bharadwaj et al., 2018), with blood MDA levels higher in the AP group compared to the NP group for the whole study period (week 2:  $117.03 \pm 120.96$  vs  $73.9 \pm 15.85$  nmol/ml;  $P = 1,0$ ; week 1:  $89.1 \pm 32.86$  vs  $53.98 \pm 19.12$  nmol/ml;  $P = 0,048$ ). However, other oxidative stress markers did not show a consistent behavior. Etiological causes for the placental diseases presented by the mares in the AP group, different placental structure and level of intimacy of maternal and fetal components of the fetoplacental unity, and possible difference in the sensitivity of the test applied to the equine species must be taken into consideration when analyzing the results presented by this study.

### **3.5. Conclusion**

This is one of the first studies carried out with the goal of assessing the oxidative status of pregnant mares with normal and abnormal pregnancies and/or parturition. Our results showed similar tendencies to studies conducted in pregnant women with placental dysfunction, but factors such as number of animals enrolled in this study, placental structure differences, specific etiology, maternal health and environment must be taken into account. Therefore, more studies must be carried out involving a greater number of animals to more accurately assess the oxidative status in normal mares and identify possible biomarkers of oxidative damage for pregnancy abnormalities in horses.

### **3.6. References**

- AEBI, H. Catalase in vitro. **Methods in Enzymology**, v.105, p.121-126, 1984.
- AL-GUBORY, K.; GARREL, C.; FAURE, P. SUGINO, N. Roles of antioxidant enzymes in corpus luteum rescue from reactive oxygen species-induced oxidative stress. **Reproductive Biomedicine Online**, v.25, n.6, p.551-560, 2012.
- AOKI, T.; YAMAKAWA, K.; ISHII, M. Factors affecting gestation length in Heavy Draft mares. **Journal of Equine Veterinary Science**, v.33, n.6, p.437-440, 2013.

AYDIN, S.; BENIAN, A.; MADAZLI, R.; ULUDAG, S.; UZUN, H.; KAYA. Plasma malondialdehyde, superoxide dismutase, sE-selectin, fibronectin, endothelin-1 and nitric oxide levels in women with preeclampsia. **European Journal of Obstetrics, Gynecology, and Reproductive Biology**, v.113, n.1, p.21-25, 2004.

BABIOR, B.M. Phagocytes and Oxidative Stress. **American Journal of Medicine**, v.109, n.1, p.33-44, 2000.

BANNISTER, J.V.; CALABRESE, L. Assays for superoxide dismutase. **Methods of Biochemical Analysis**, v.32, p.279-312, 1987.

BENZIE, I.F.; STRAIN, J.J. The ferric reducing ability of plasma (FRAP) as a measure of "antioxidant power": the FRAP assay. **Analytical Biochemistry**, v.239, n.1, p.70-76, 1996.

BHARADWAJ, S.K.; BHAT, B.V.; VICKNESWAARAN, V.; ADHISIVAM, B.; BOBBY, Z.; HABEEBULLAH, S. Oxidative Stress, Antioxidant Status and Neurodevelopmental Outcome in Neonates Born to Pre-eclamptic Mothers. **Indian Journal of Pediatrics**, v.85, n.5, p.351-357, 2018.

BRADFORD, M.M. A rapid and sensitive method for the quantitation of microgram quantities of protein utilizing the principle of protein-dye binding. **Analytical Biochemistry**, v.72, n.7, p.248-254, 1976.

BUCCA, S.; FOGARTY, U.; COLLINS, A.; SMALL, V. Assessment of fetoplacental well-being in the mare from mid-gestation to term: transrectal and transabdominal ultrasonographic features. **Theriogenology**, v.64, n.3, p.542-557, 2005.

CANISSO, I.F.; BALL, B.A.; EROL, E.; SQUIRES, E.L.; TROEDSSON, M. Comprehensive review on equine placentitis. **Proceedings of the American Association of Equine Practitioners**, v.61, p.490-509, 2015.

CECCHINI, S.; FAZIO, F.; BAZZANO, M.; CAPUTO, A.R.; GIANNETTO, C.; PICCIONE, G. Redox status and oxidative stress during late pregnancy and postpartum period in mares. **Livestock Science**, v.230, 103821, 2019.

COLÓN, J.L. Trans-Rectal Ultrasonographic Appearance of Abnormal Combined Utero-Placental Thickness in Late-Term Gestation and its Incidence During Routine Survey in a Population of Thoroughbred Mares (2005-2008). **Proceedings of the American Association of Equine Practitioners**, v.54, p.279-285, 2008.

CUERVO-ARANGO, J.; NEWCOMBE, J.R. The Effect of Manual Removal of Placenta Immediately after Foaling on Subsequent Fertility Parameters in the Mare. **Journal of Equine Veterinary Science**, v.29, n.11, p.771-774, 2009.

DAVIES MOREL, M.C.G.; NEWCOMBE, J.R.; HOLLAND, S.J. Factors affecting gestations length in the Thoroughbred mare. **Animal Reproduction Science**, v.74, n.3-4, p.175-185, 2002.

DRAPER, H.H.; HADLEY, M. Malondialdehyde determination as index of lipid peroxidation. **Methods in Enzymology**, v.186, p.421-431, 1990.

DRÖGE, W. Free radicals in the physiological control of cell function. **Physiological Reviews**, v.82, n.1, p.47-95, 2002.

FINKEL, T. Signal transduction by reactive oxygen species. **Journal of Cell Biology**, v.194, n.1, p.7-15, 2011.

FRAZER, G.S. *Post partum* complications in the mare. Part 2: Fetal membrane retention and conditions of the gastrointestinal tract, bladder and vagina. **Equine Veterinary Education**, v.15, n.2, p.91-100, 2003.

GUÉRIN, P.; MOUATASSIM, S.E.; MÉNÉZO, Y Oxidative stress and protection against reactive oxygen species in the pre-implantation embryo and its surroundings. **Human Reproduction Update**, v.7, n.2, p.175-189, 2001.

HALLIWELL, B. Reactive oxygen species and the central nervous system. **Journal of Neurochemistry**, v.59, n.1, p.609-623, 1992.

JENKIN, G.; YOUNG, I.R. Mechanisms responsible for parturition; the use of experimental models. **Animal Reproduction Science**, v.82, p.567-581, 2004.

KUMAR, C.A.; DAS, U.N. Lipid peroxides, anti-oxidants and nitric oxide in patients with pre-eclampsia and essential hypertension. **Medical Science Monitor: International Medical Journal of Experimental and Clinical Research**, v.6, n.5, p.901-907, 2000.

LEBLANC, M.M. Common peripartum problems in the mare. **Journal of Equine Veterinary Science**, v.28, n.11, p.709-715, 2008.

LEVINE, R.L.; GARLAND, D.; OLIVER, C.N.; AMICI, A.; CLIMENT, I.; LENZ, A.G.; AHN, B.W.; SHALTIEL, S.; STADTMAN, E.R. Determination of carbonyl content in oxidatively modified proteins. **Methods in Enzymology**, v.186, p.464-478, 1990.

LOVERRO, G.; GRECO, P.; CAPUANO, F.; CARONE, D.; CORMIO, G.; SELVAGGI, L. Lipoperoxidation and antioxidant enzymes activity in pregnancy complicated with hypertension. **European Journal of Obstetrics, Gynecology, and Reproductive Biology**, v.70, n.2, p.123-127, 1996.

MADAZLI, R.; BENIAN, A.; AYDIN, S.; UZUN, H.; TOLUN, N. The plasma and placental levels of malondialdehyde, glutathione and superoxide dismutase in pre-eclampsia. **Journal of Obstetrics and Gynaecology**, v.22, n.5, p.477-480, 2002.

MANN, P.J.G.; QUASTEL, J.H. Toxic effects of oxygen and of hydrogen peroxide on brain metabolism. **Biochemical Journal**, v.40, n.1, p.139-144, 1946.

MASUMOTO, N.; TASAKA, K.; MIYAKE, A.; TANIZAWA, O. Superoxide anion increases intracellular free calcium in human myometrial cells. **Journal of Biological Chemistry**, v.265, n.36, 22533-22536, 1990.

MATALON, S.; HARDIMAN, K.M.; JAIN, L.; EATON, D.C.; KOTLIKOFF, M.; EU, J.P.; SUN, J.; MEISSNER, G.; STAMLER, J. Regulation of ion channel structure and function by reactive oxygen-nitrogen species. **American Journal of Physiology: Lung, Cellular & Molecular Physiology**, v.285, L1184-L1189, 2003.

MARTINDALE, J.L.; HOLBROOK, N.J. Cellular response to oxidative stress, signaling for suicide and survival. **Journal of Cellular Physiology**, v.192, n.1, p.1-15, 2002.

MCCONKEY, D.J.; ORRENIUS, S. The role of calcium in the regulation of apoptosis. **Biochemical & Biophysical Research Communications**, v.239, n.2 p.357-366, 1997.

MYATT, L.; CUI, X. Oxidative stress in the placenta. **Histochemistry & Cell Biology**, v.122, n.4, p.369-382, 2004.

NAKAI, K.; TSURUTA, D. What are Reactive Oxygen Species, Free Radicals, and Oxidative Stress in Skin Disease?. **International Journal of Molecular Sciences**, v.22, 107999, 2021.

PIZZINO, G.; IRRERA, N.; CUCINOTTA, M.; PALLIO, G.; MANNINO, F.; ARCORACI, V.; SQUADRITO, F.; ALTAVILLA, D.; BITTO, A. Oxidative Stress: Harms and Benefits for Human Health. **Oxidative Medicine and Cellular Longevity**, 8416763, 2017.

RANI, N.; DHINGRA, R.; ARYA, D.S.; KALAIVANI, M.; BHATLA, N.; KUMAR, R. Role of oxidative stress markers and antioxidants in the placenta of preeclamptic patients. **Journal of Obstetrics and Gynaecology Research**, v.36, n.6, p.1189-1194, 2010.

RAY, P.D.; HUANG, B.; TSUJI, Y. Reactive oxygen species (ROS) homeostasis and redox regulation in cellular signaling. **Cellular Signaling**, v.24, n.5, p.981-990, 2012.

REEF, V.B.; VAALA, W.E.; WORTH, L.T.; SERTICH, P.L.; SPENCER, P.A. Ultrasonographic assessment of fetal well-being during late gestation: development of an equine biophysical profile. **Equine Veterinary Journal**, v.28, n.3, p.200-208, 1996.

RENAUDIN, C.D.; TROEDSSON, M.H.; GILLIS, C.L.; KING, V.L.; BODENA, A. Ultrasonographic evaluation of the equine placenta by transrectal and transabdominal approach in the normal pregnant mare. **Theriogenology**, v.47, n.2, p.559-573, 1997.

SGORBINI, M.; BONELLI, F.; ROTA, A.; MARMORINI, P.; BIAGI, G.; CORAZZA, M.; PASQUINI, A. Maternal and neonatal evaluation of derivated reactive oxygen metabolites (d-ROMs) and biological antioxidant potential in the horse. **Theriogenology**, v.83, n.1, p.48-51, 2015.

SIES, H. Oxidative Stress: From Basic Research to Clinical Application. **The American Journal of Medicine**, v.91, (suppl 3C), p.31-38, 1991.

SHIRAI, F.; KAWAGUCHI, M.; YUTSUDO, M.; DOHI, Y. Human peripheral blood polymorphonuclear leukocytes at the ovulatory period are in an activated state. **Molecular & Cellular Endocrinology**, v.196, n.1-2, p.21– 28, 2002.

SUGINO, N. Reactive oxygen species in ovarian physiology. **Reproductive Medicine & Biology**, v.4, n.1, p.31-44, 2005.

THRELFALL, W.R. Retained Fetal Membranes. In: MCKINNON, A.O.; SQUIRES, E.L.; VAALA, W.E.; VARNER, D.D. **Equine Reproduction**. 2nd edition. Chichester: Wiley-Blackwell, 2011. p.2520-2529.

TIWARI, M.; CHAUBE, S. Moderate increase of reactive oxygen species triggers meiotic resumption in rat follicular oocytes. **Journal of Obstetrics & Gynecology Research**, v.42, n.5, p.536-546, 2016.

TROEDSSON, M.H.T.; MACPHERSON, M.L. Placentitis. In: MCKINNON, A.O.; SQUIRES, E.L.; VAALA, W.E.; VARNER, D.D. **Equine Reproduction**. 2nd edition. Chichester: Wiley-Blackwell, 2011. p.2359-2367.

TROEDSSON, M.H.T.; RENAUDIN, C.D.; ZENT, W.W.; STEINER, J.V. Transrectal Ultrasonography of the Placenta in Normal Mares and Mares with Pending Abortion:

A Field Study. **Proceedings of the American Association of Equine Practitioners**, v.43, p.256-258, 1997.

VANDESPLASSCHE, M.; SPINCEMAILLE, J.; BOUTERS, R. Aetiology, pathogenesis and treatment of retained placenta in the mare. **Equine Veterinary Journal**, v.3, n.4, p.144-147, 1971.

WISDOM, S.J.; WILSON, R.; MCKILLOP, J.H.; WALKER, J.J. Antioxidant systems in normal pregnancy and in pregnancy-induced hypertension. **American Journal of Obstetrics & Gynecology**, v.165, n.6 (Pt.1), p.1701-1704, 1991.

ZHANG, J.; WANG, X.; VILLASH, V.; YE, Q.; WU, D.; LIU, Y.; DONG, W. ROS and ROS-Mediated Cellular Signaling. **Oxidative Medicine and Cellular Longevity**, 4350965, 2016.